

# Sono Facts

The text "Sono Facts" is centered on the page. It is surrounded by six light purple circles. Three circles are arranged in a horizontal line above the text, and three are arranged in a horizontal line below it. The top-left and bottom-right circles are hollow with a thin purple outline, while the other four circles are solid light purple.

The text is centered on a white background. It is surrounded by six light purple circles of varying sizes and positions. Two circles are solid purple, while the other four are hollow with a thin purple outline. The circles are arranged in a loose, abstract pattern around the text.

What makes up the  
“Sea Gull” sign?




- Celiac Axis
- Hepatic Artery
- Splenic Artery

Answer



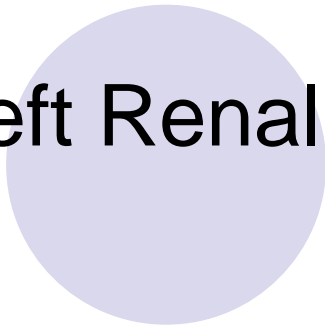


What renal vessel goes posterior to the SMA and anterior to the Aorta to enter the IVC?

- Left Renal Vein

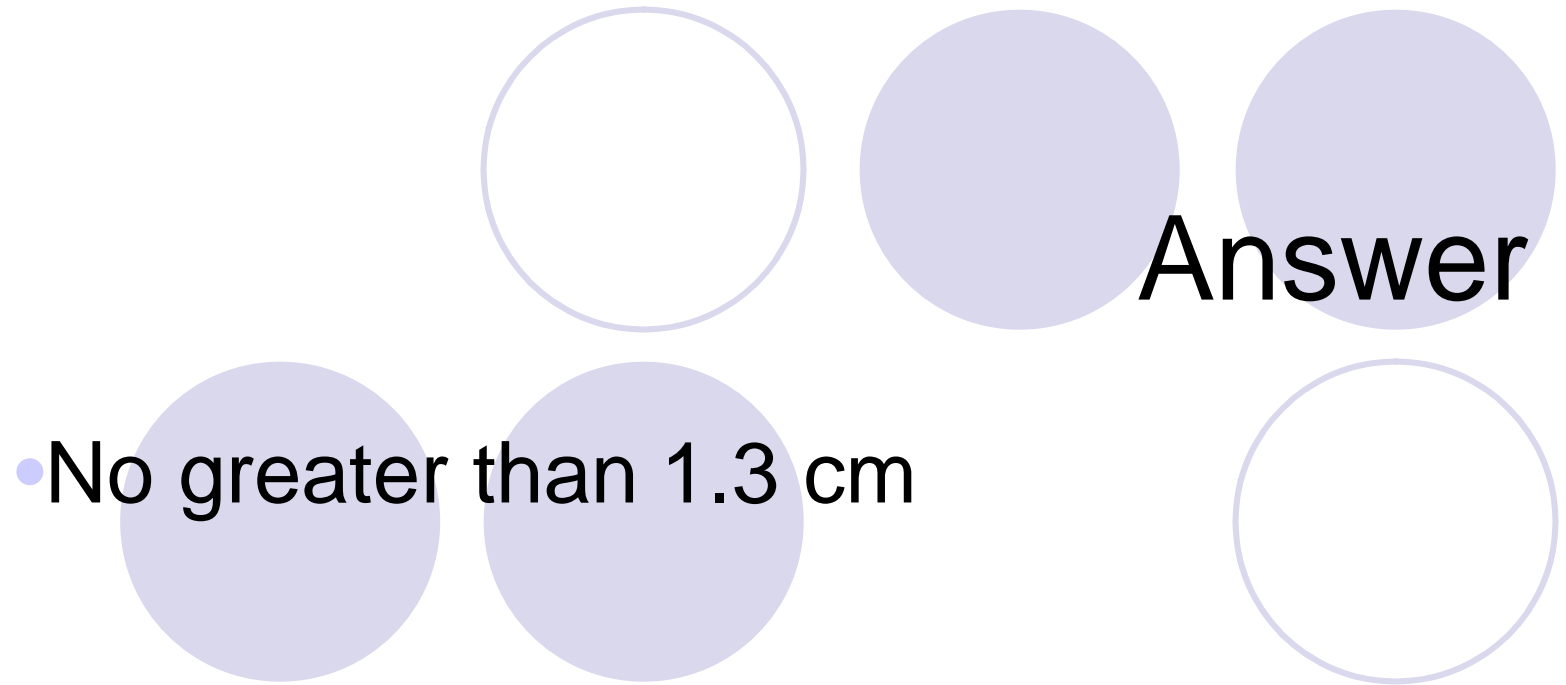


**Answer**





What should the measurement of the Portal Vein be?



**Answer**

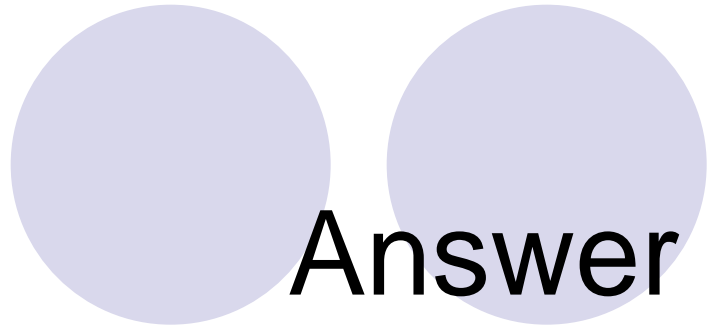

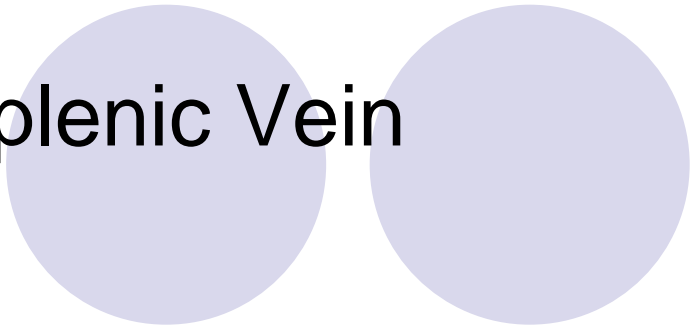
- No greater than 1.3 cm




What vessel courses posterior to the pancreas to join the SMV to form the main portal vein?



• Splenic Vein






**Answer**






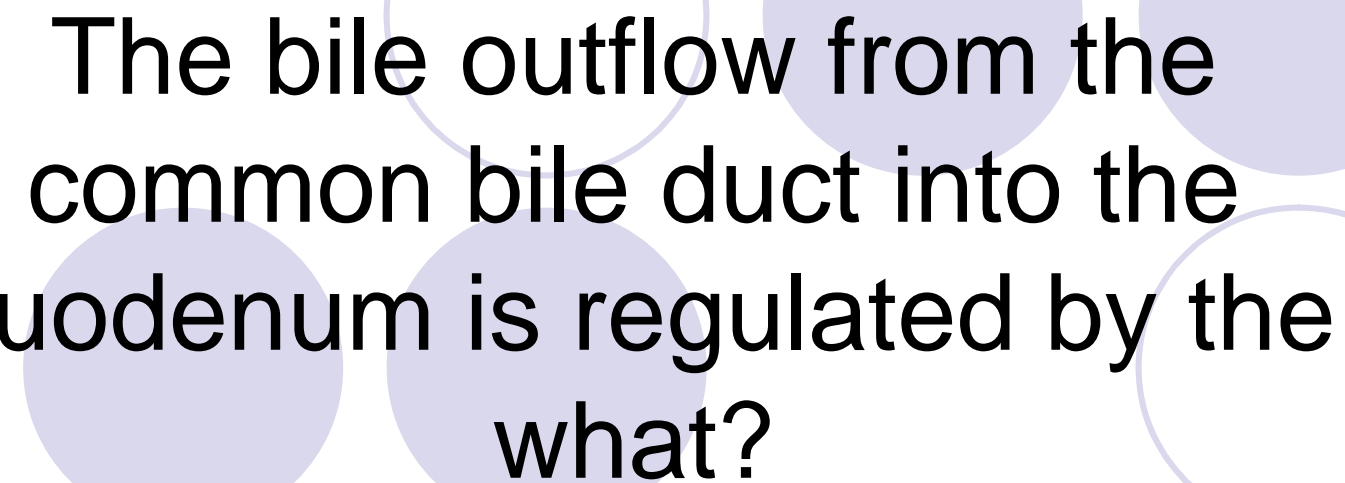
**What is the portal confluence  
composed of?**

- SMV
- Splenic Vein
- Portal Vein






**Answer**




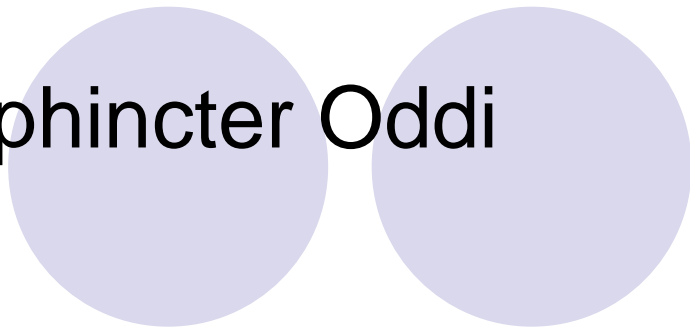


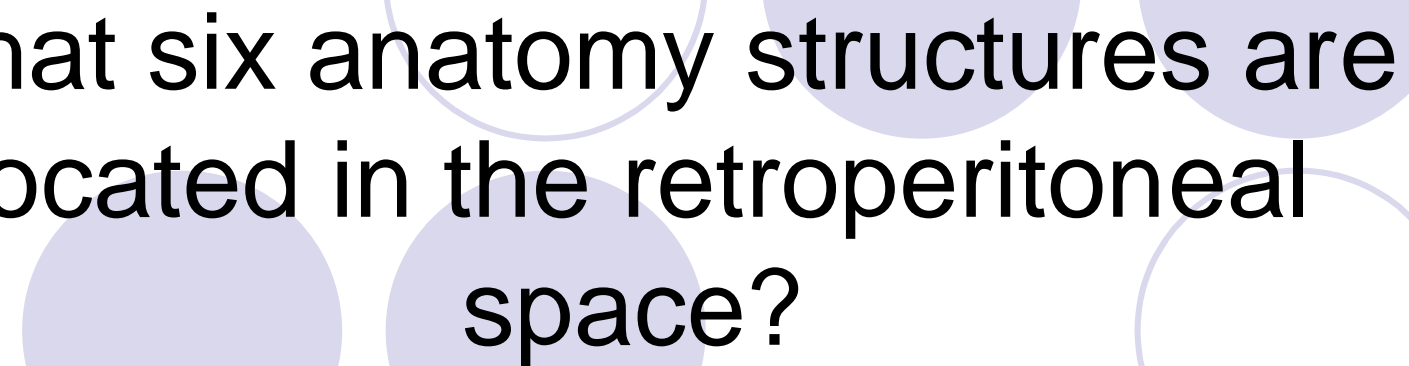
The bile outflow from the common bile duct into the duodenum is regulated by the what?

• Sphincter Oddi






Answer







What six anatomy structures are located in the retroperitoneal space?

- Kidneys
- Pancreas
- Aorta
- IVC
- Adrenal glands
- Psoas muscles
- Duodenum



**Answer**










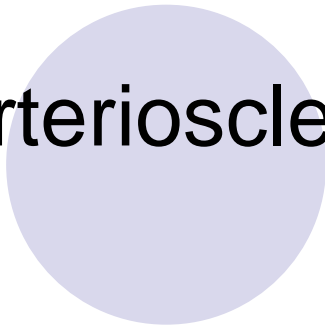
**What is the most common  
cause of aortic aneurysms?**

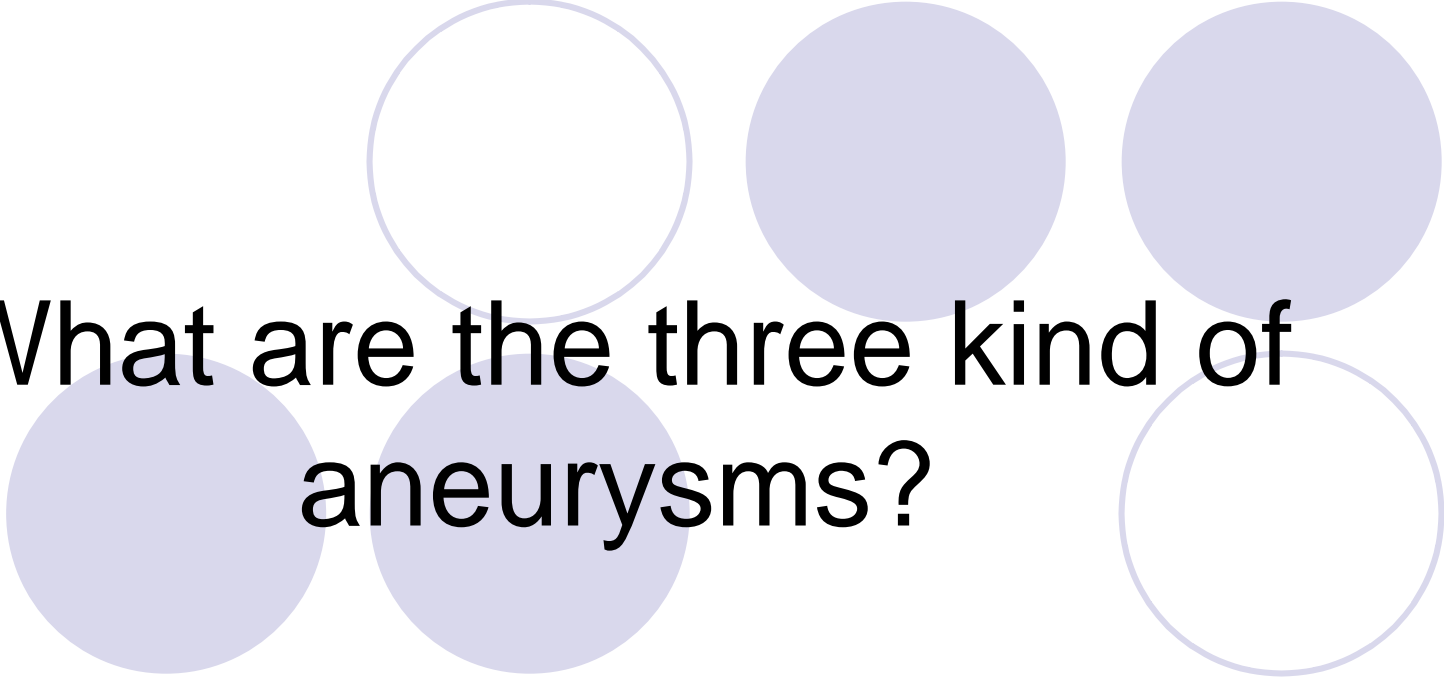


- Arteriosclerosis






**Answer**







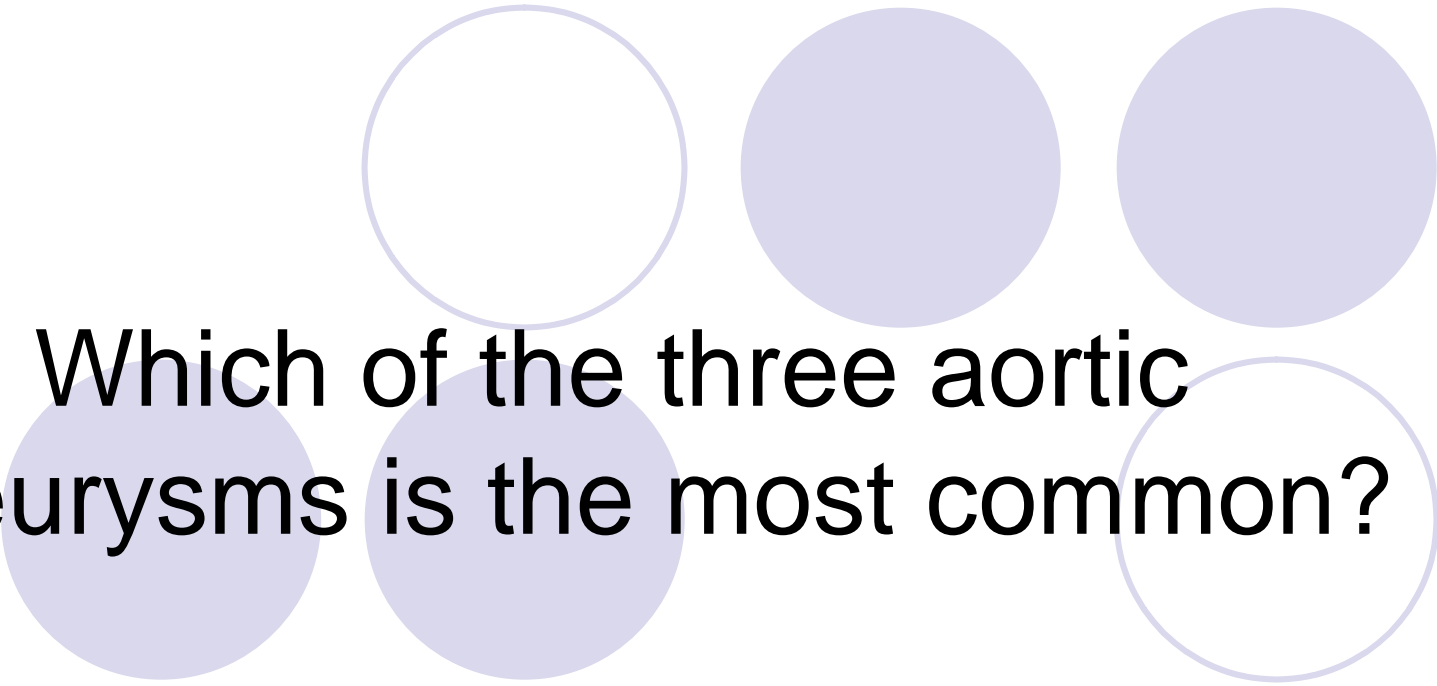
**What are the three kind of  
aneurysms?**

- Saccular
- Fusiform
- Berry







**Answer**






Which of the three aortic aneurysms is the most common?

• Fusiform



Answer





**The umbilical vein turns into  
what structure after birth?**

• Ligamentum Teres

Answer

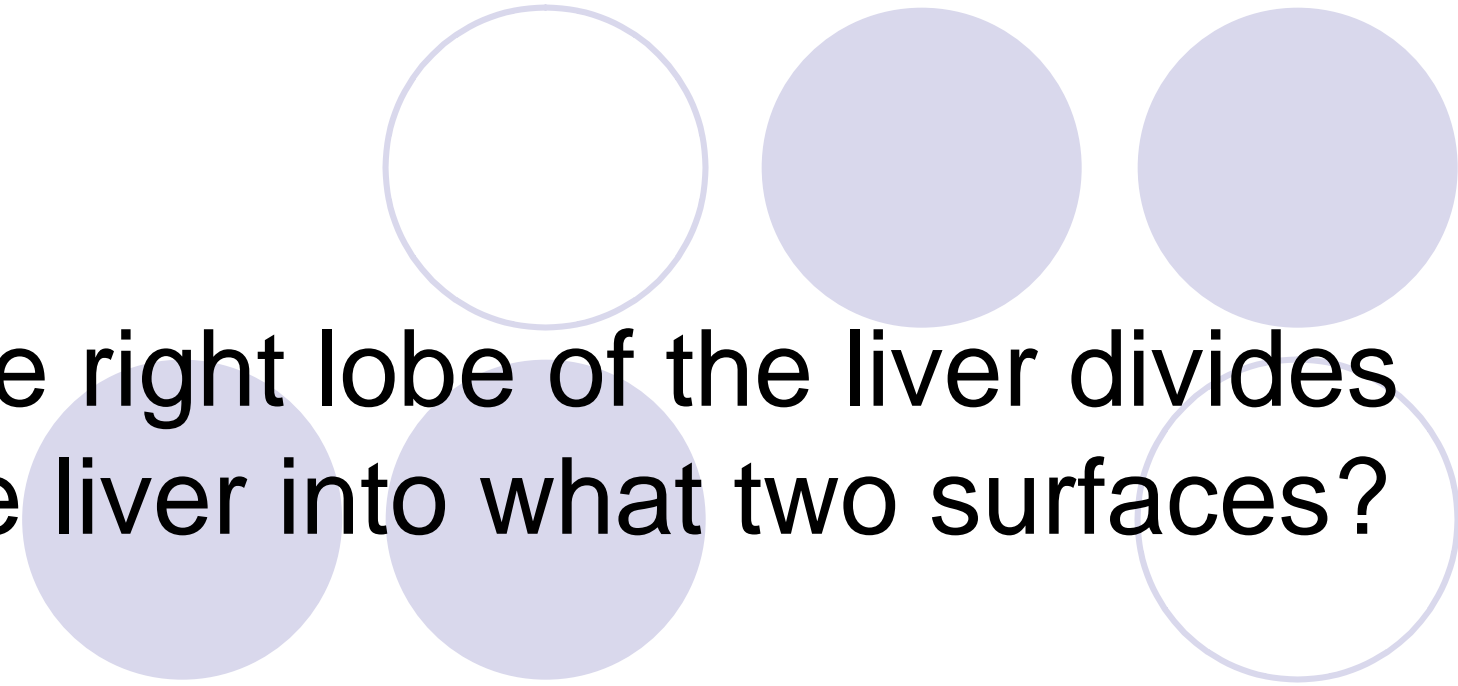


The ductus venosus turns into  
what structure after birth?






- Ligamentum of Venosus

Answer





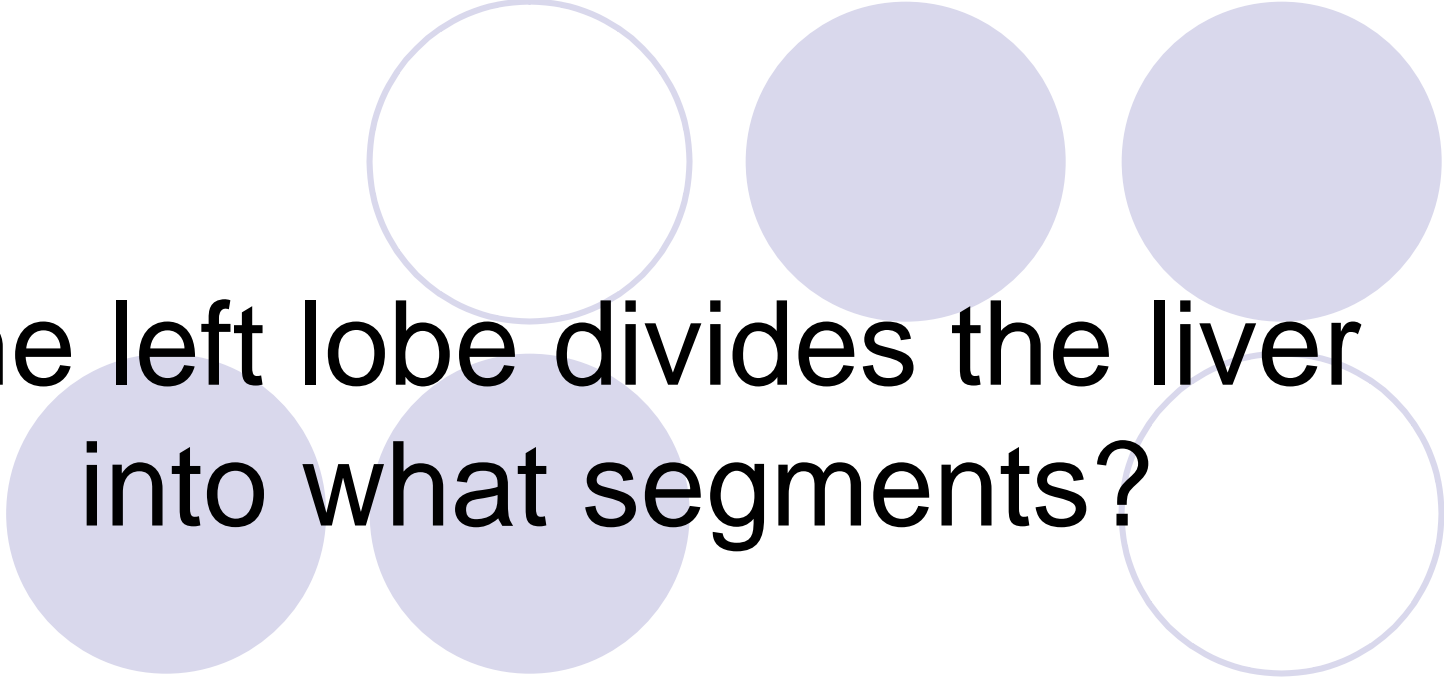
The right lobe of the liver divides the liver into what two surfaces?

- Anterior
- Posterior






**Answer**







**The left lobe divides the liver  
into what segments?**

- Medial
- Lateral




**Answer**

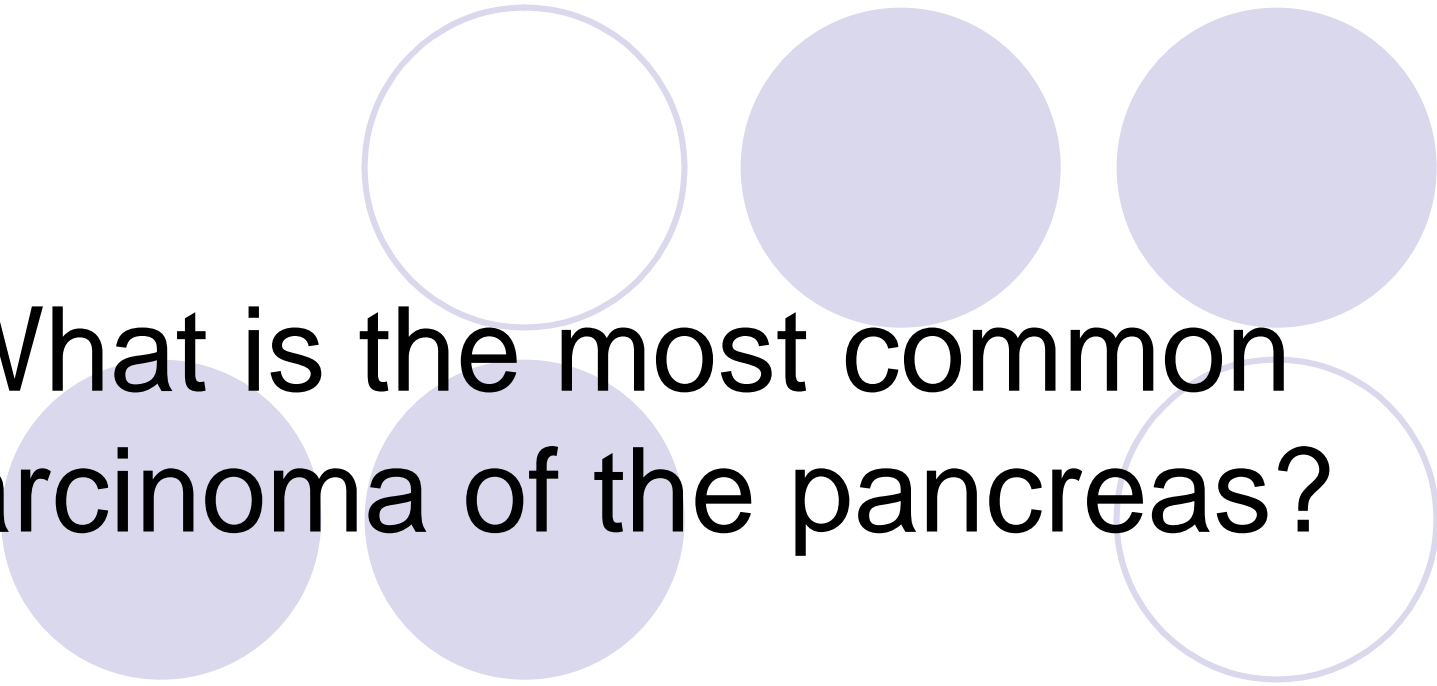




The main lobar fissure divides the liver into what true lobes?

- Right
- Left



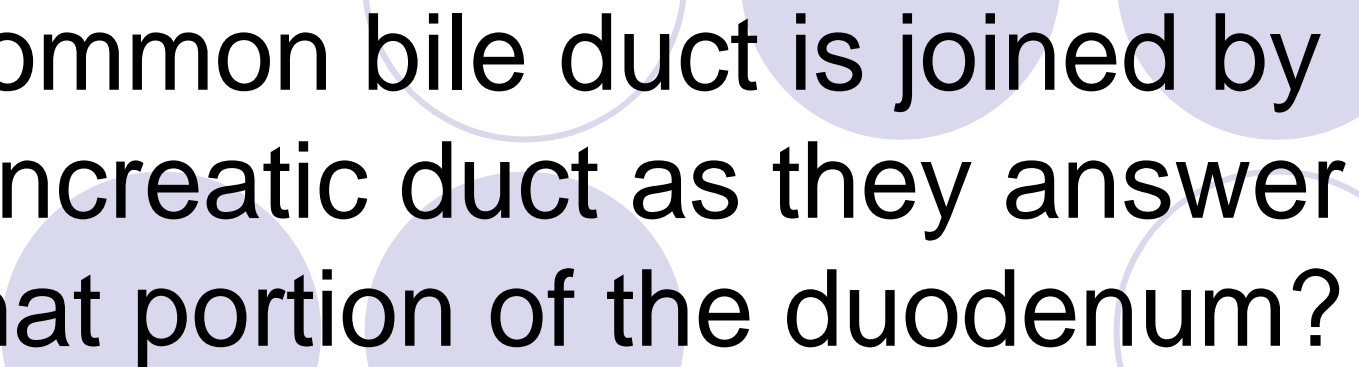


**What is the most common carcinoma of the pancreas?**






• Adenocarcinoma

Answer



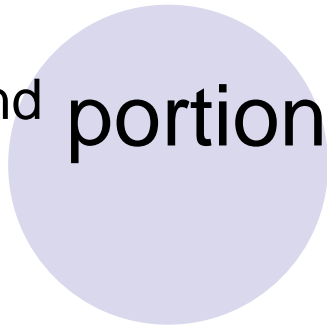


Common bile duct is joined by pancreatic duct as they answer what portion of the duodenum?

• 2<sup>nd</sup> portion



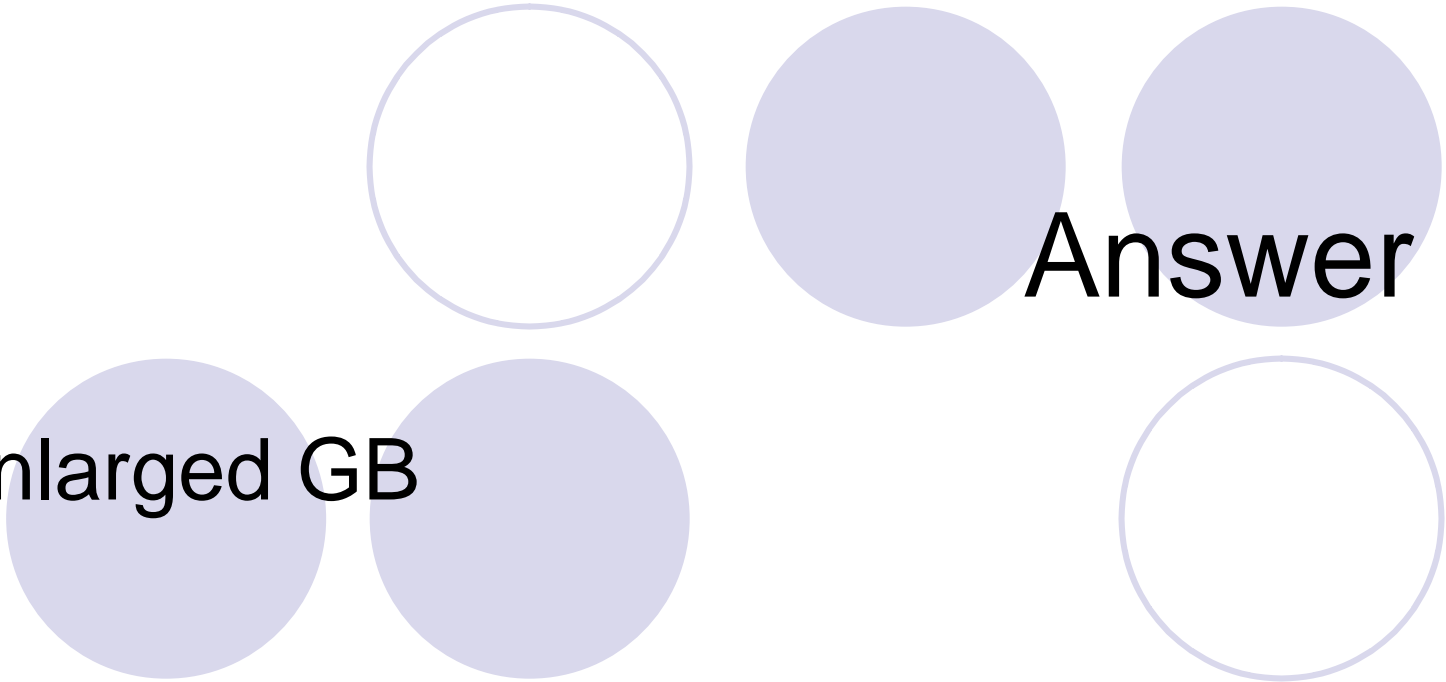
Answer

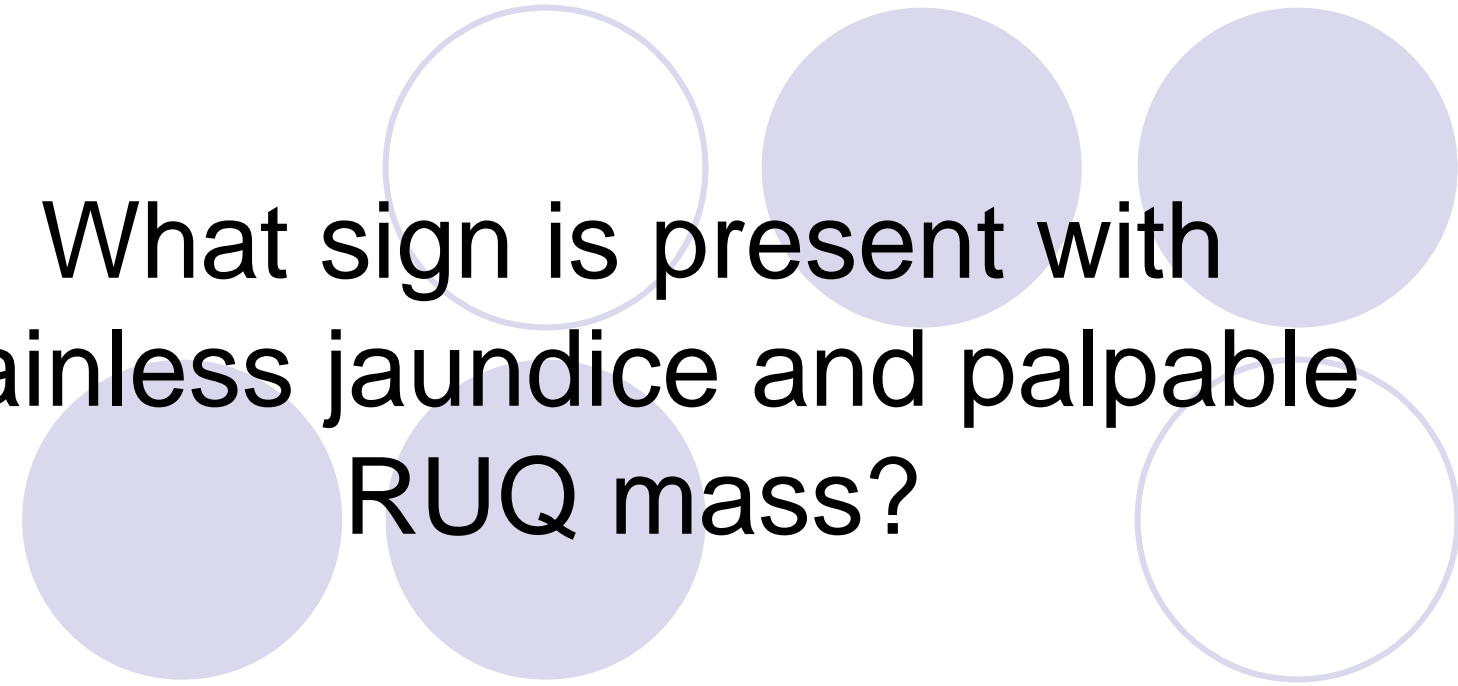




**What is hydrops of the GB?**



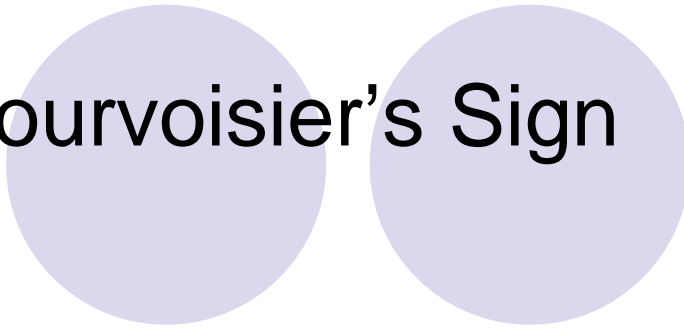
- Enlarged GB






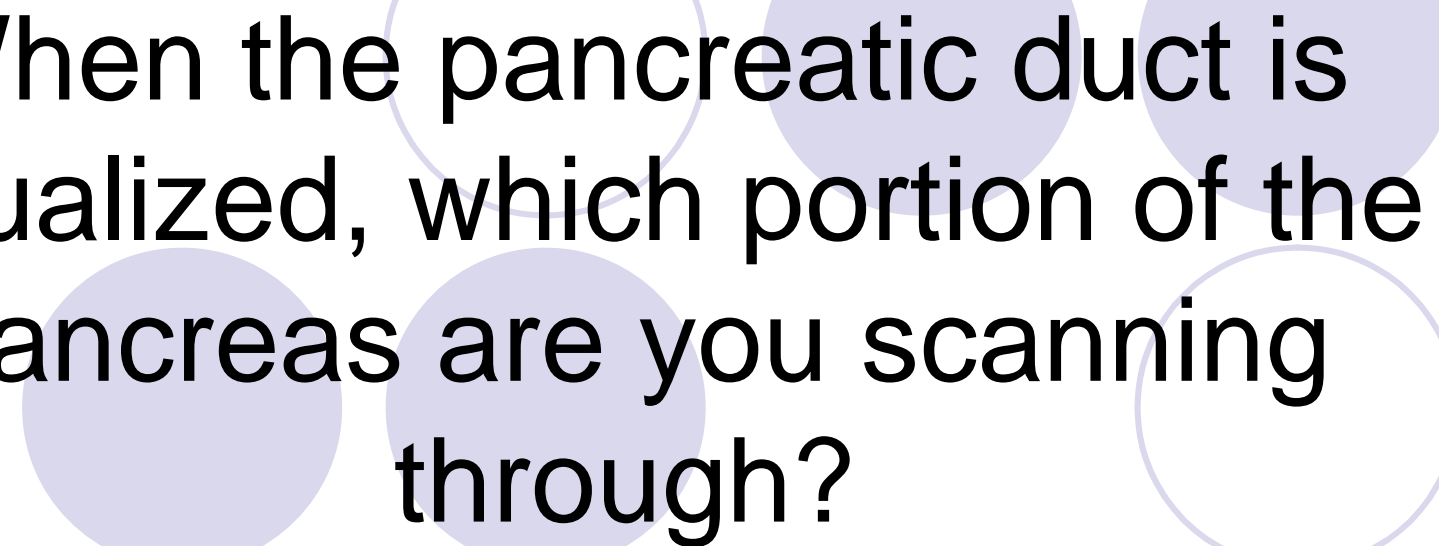
What sign is present with  
painless jaundice and palpable  
RUQ mass?

• Courvoisier's Sign



Answer





When the pancreatic duct is visualized, which portion of the pancreas are you scanning through?






- Body of Pancreas

Answer





The pancreatic duct should  
measure no larger than?

• 2 – 3 mm








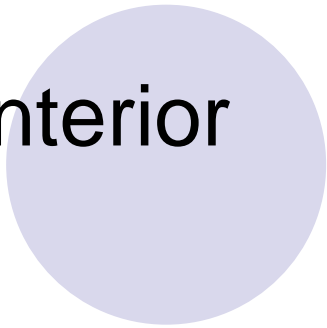
**Answer**



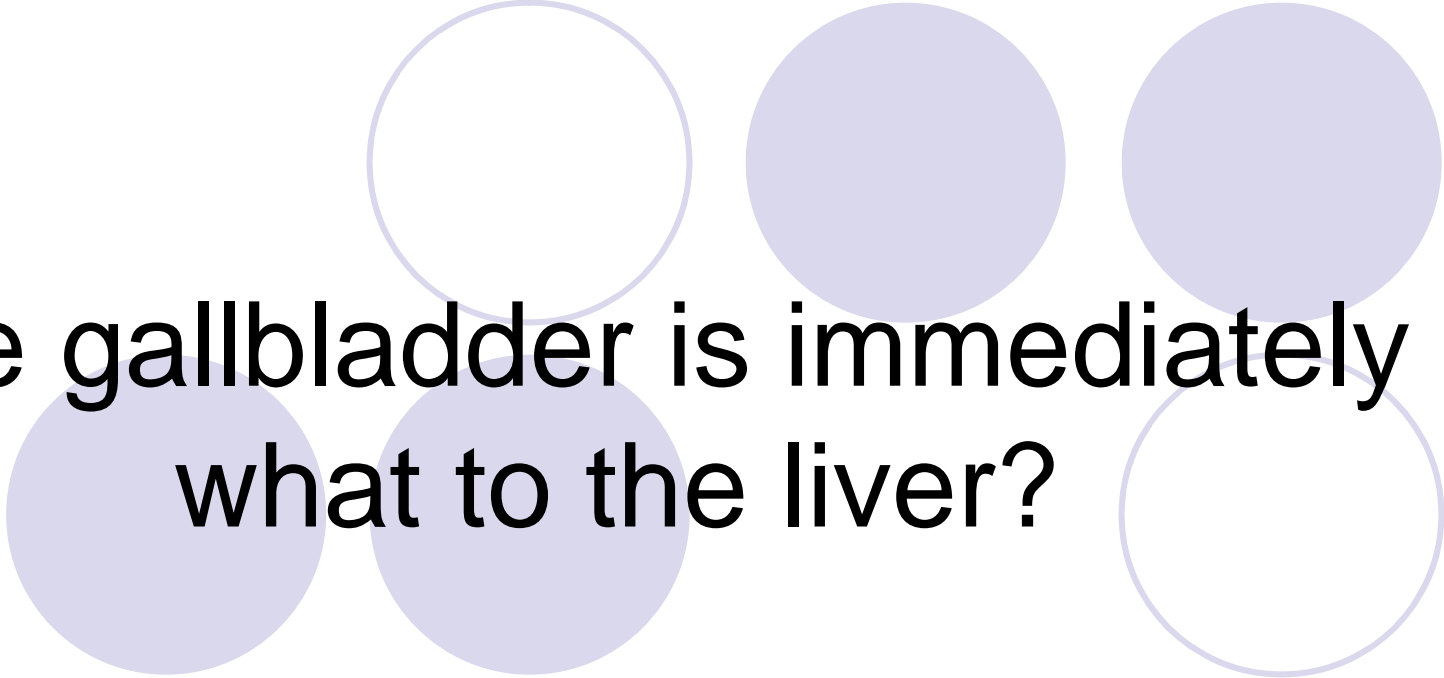


The fundus of GB is black to superior pole of the kidney?

• Anterior





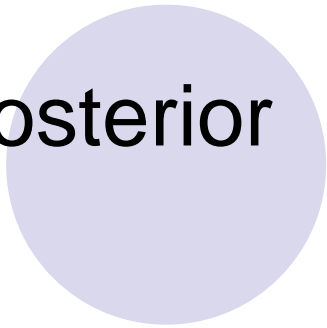


Answer

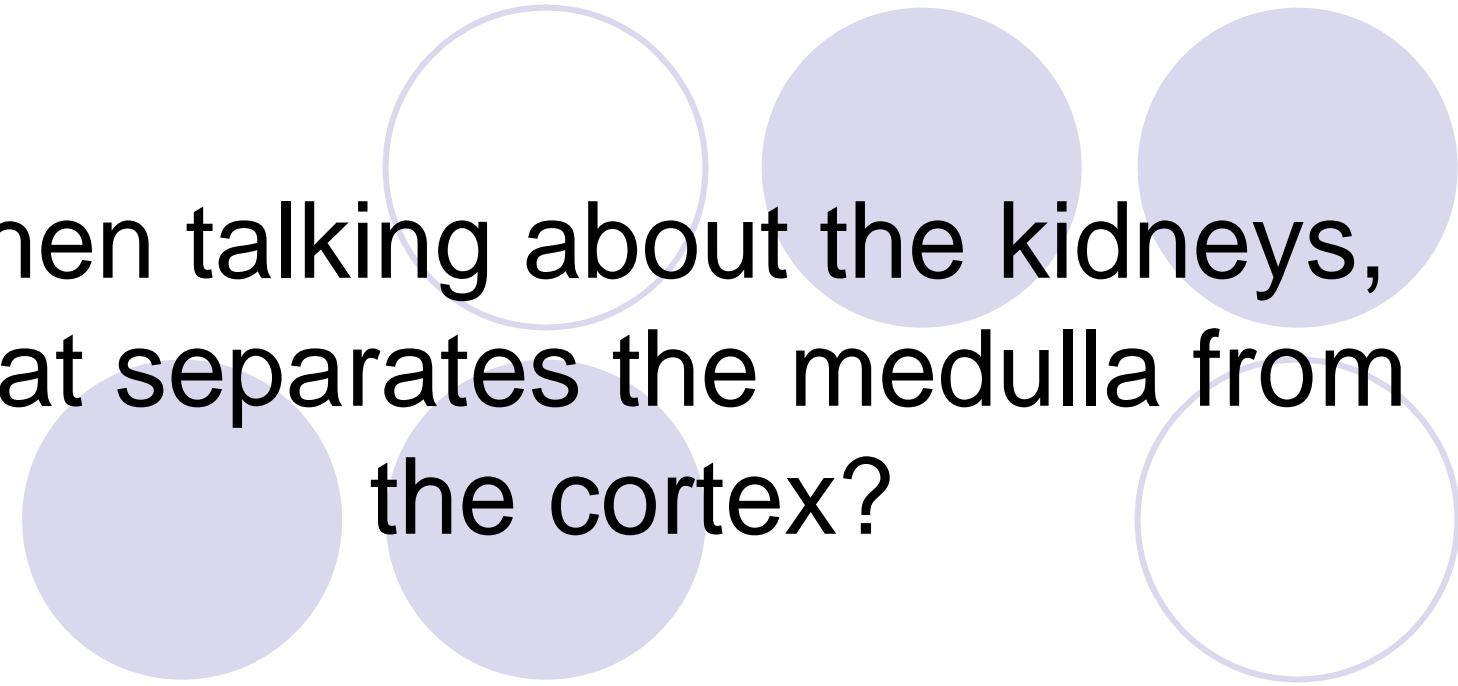


**The gallbladder is immediately  
what to the liver?**

• Posterior






Answer




When talking about the kidneys,  
what separates the medulla from  
the cortex?



- Arcuate Vessels









**Answer**





**What is the functional portion  
of the kidney?**

• Nephrons



Answer



**What does the nephron  
contain?**






- Bowman's Capsule
- Glomerulus

Answer



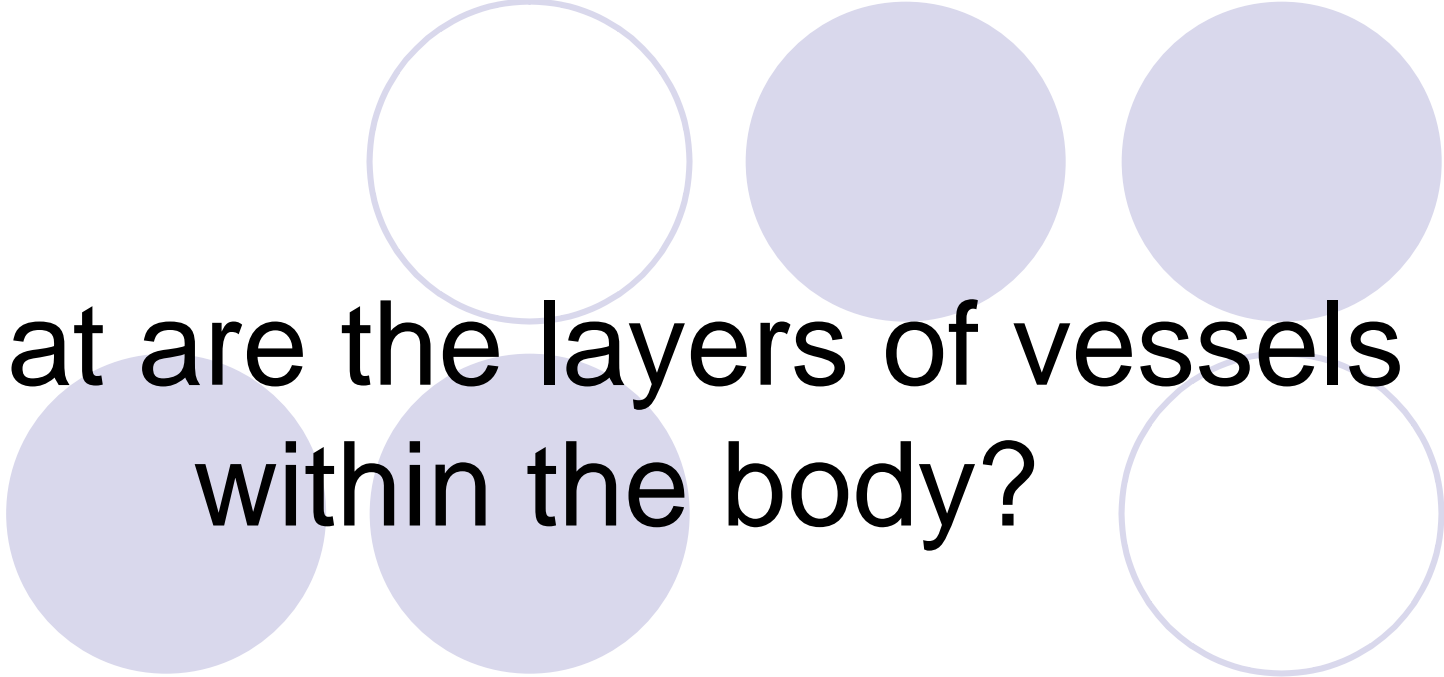
The gallbladder wall should be  
no greater than?

• 3 mm



**Answer**



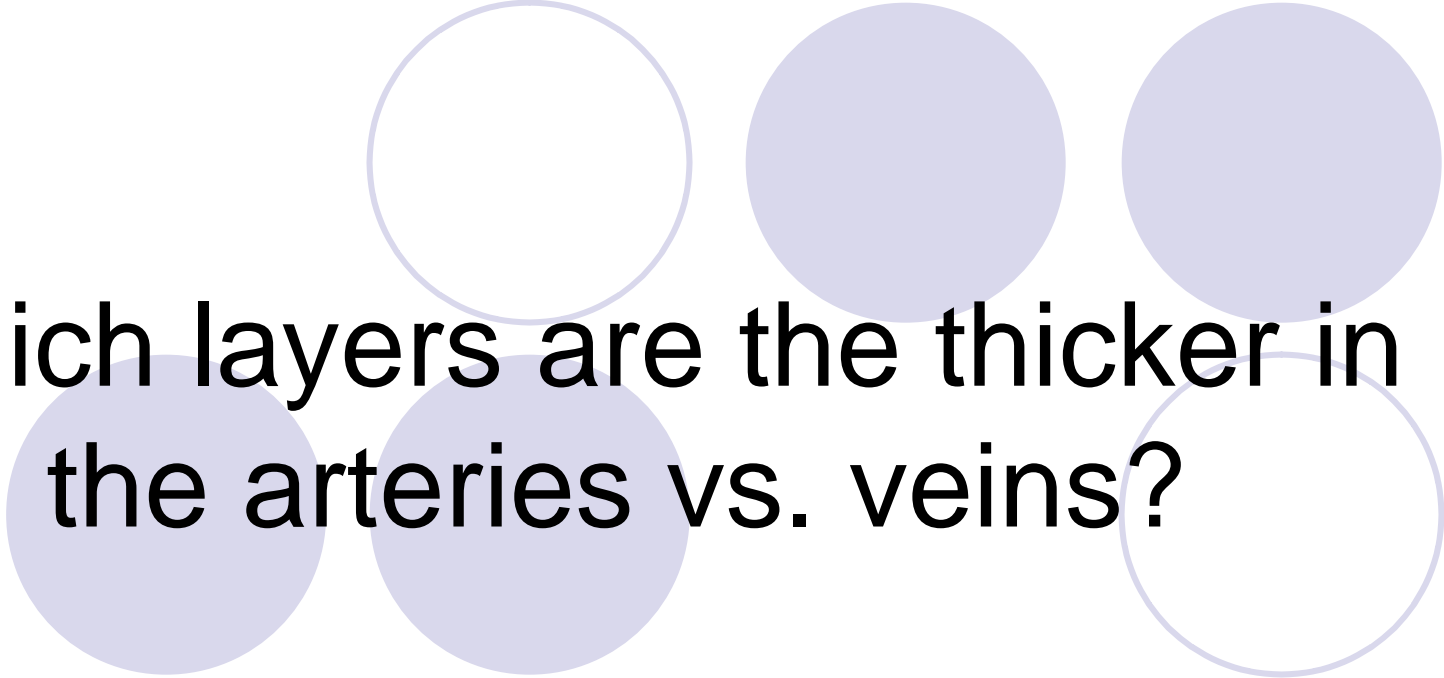


**What are the layers of vessels  
within the body?**



- Tunica intima
- Tunica media
- Tunica adventitia

Answer



**Which layers are the thicker in the arteries vs. veins?**







- Tunica Media
- Tunica Adventitia

**Answer**

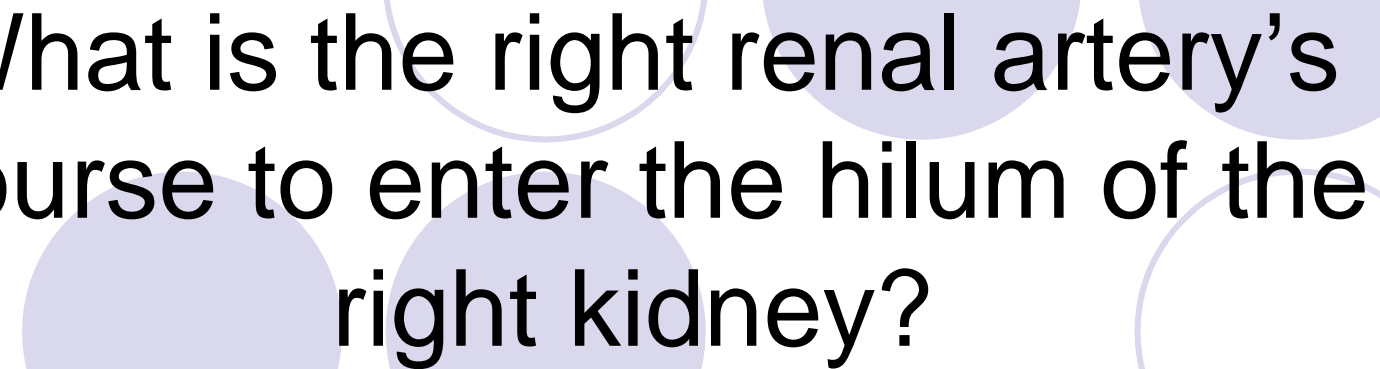


Which renal artery is longer in length?




• Right



Answer




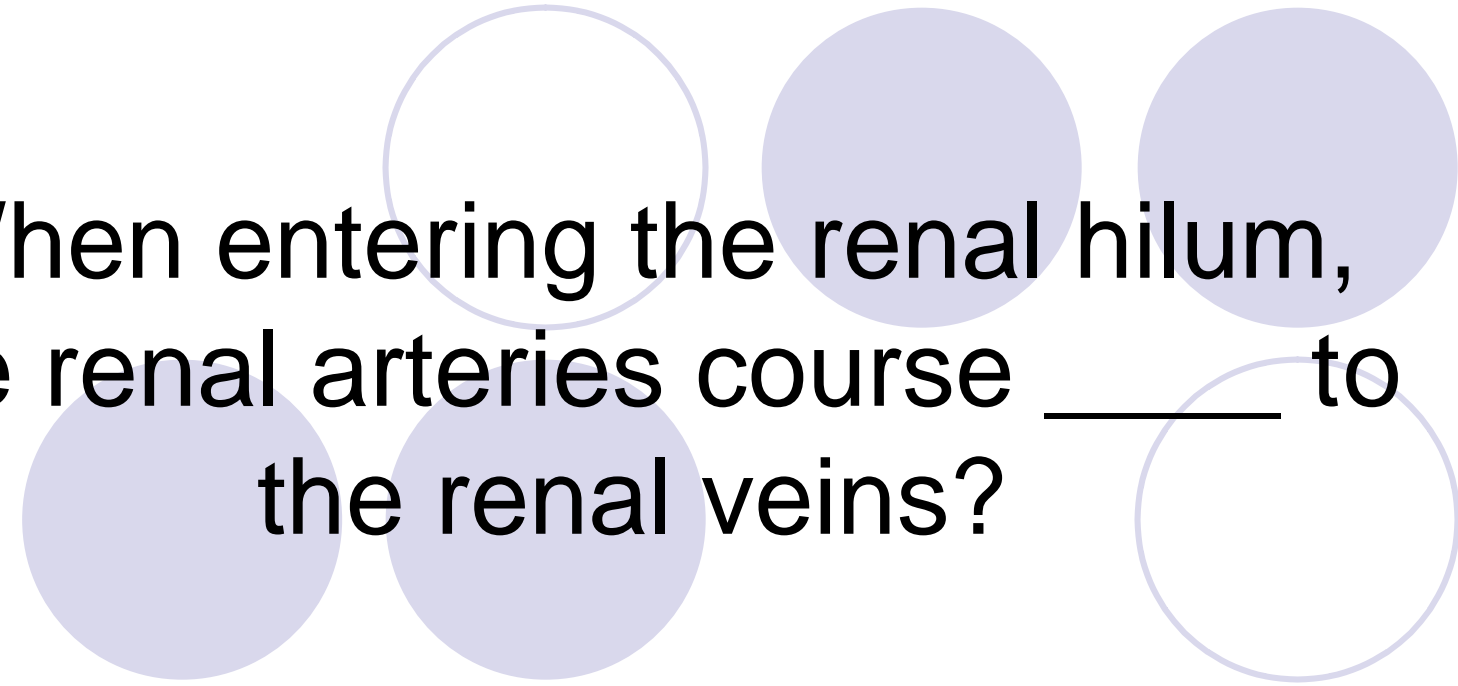
What is the right renal artery's course to enter the hilum of the right kidney?



**Answer**

- It courses posterior to the IVC





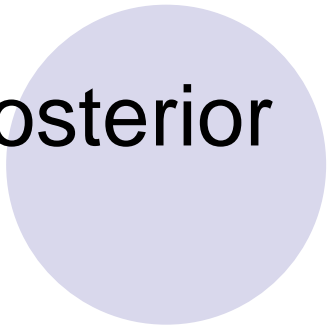




When entering the renal hilum,  
the renal arteries course \_\_\_\_\_ to  
the renal veins?



• Posterior



Answer