



Normal Anatomy

Size Ranges & Protocols

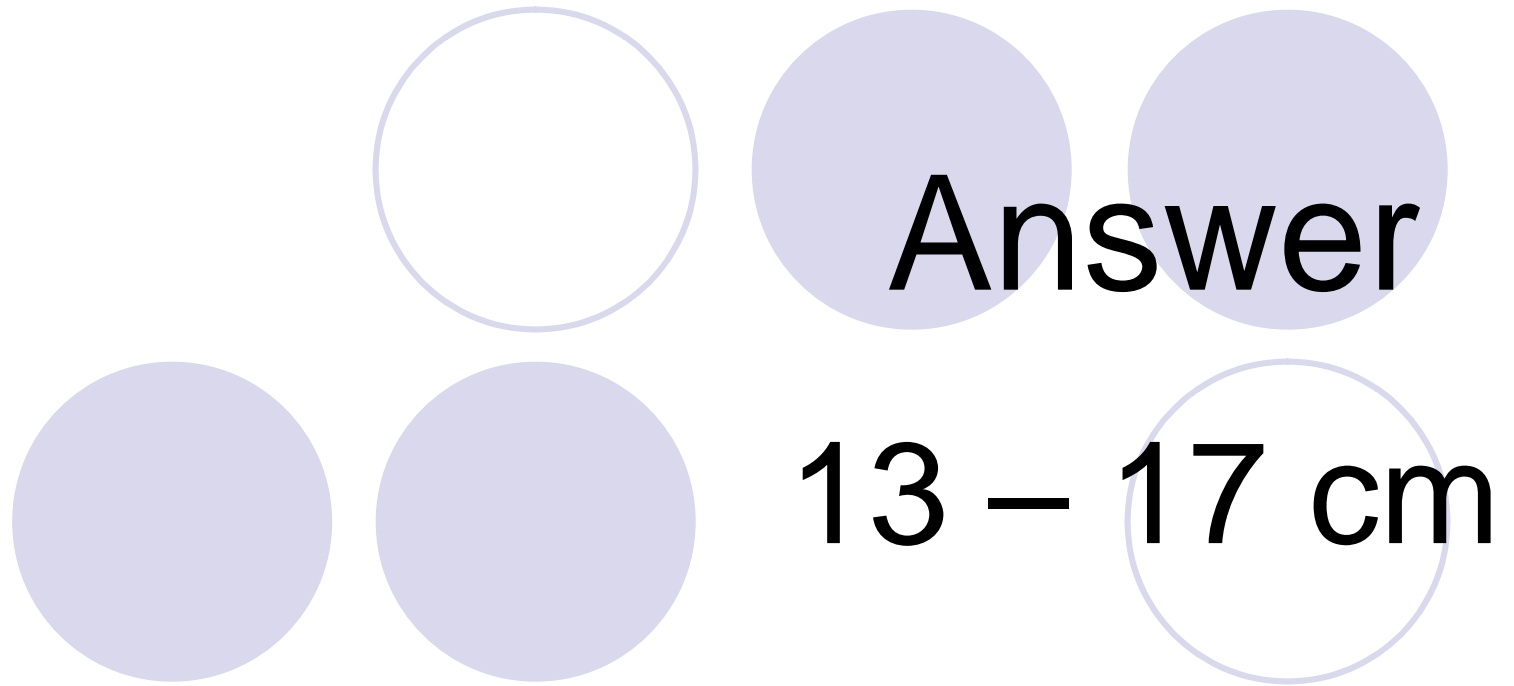
Sonography Jeopardy


Liver	GB & Biliary Sys	Renal & Thyroid	Pancreas & Spleen	Anatomy General
<u>1pt</u>	<u>1 pt</u>	<u>1 pt</u>	<u>1pt</u>	<u>1 pt</u>
<u>2 pt</u>	<u>2 pt</u>	<u>2pt</u>	<u>2pt</u>	<u>2 pt</u>
<u>3 pt</u>	<u>3 pt</u>	<u>3 pt</u>	<u>3 pt</u>	<u>3 pt</u>
<u>4 pt</u>	<u>4 pt</u>	<u>4pt</u>	<u>4 pt</u>	<u>4pt</u>
<u>5pt</u>	<u>5 pt</u>	<u>5 pt</u>	<u>5 pt</u>	<u>5 pt</u>



Liver Pt. 1

What is the AP size range for the right lobe of liver?

**Answer**
13 – 17 cm






Liver Pt. 2

The portal vein should
measure?

The text is surrounded by five light purple circles. One circle is empty and located at the top left. Two circles are filled and located at the top right, with the word 'Answer' centered between them. Two circles are filled and located at the bottom left and bottom center, with the text '1.3 cm or 13 mm' centered between them. One empty circle is located at the bottom right.

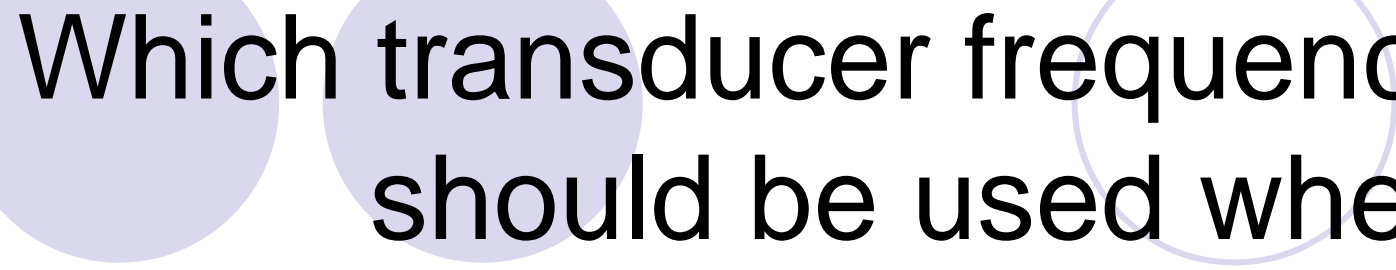
Answer

1.3 cm or 13 mm





Liver Pt. 3




Which transducer frequency should be used when scanning the liver?

The slide features several decorative circles. There are five solid light purple circles and two hollow light purple circles. The word "Answer" is centered within one of the solid circles.

Answer

3.0 MHz or 3.5 MHz




The slide features a decorative arrangement of five circles. At the top, there is one white circle with a thin purple outline on the left, and two solid purple circles on the right. Below these, there are three solid purple circles on the left and one white circle with a thin purple outline on the right. The text 'Liver Pt. 4' is centered between the top two rows of circles.

Liver Pt. 4

When scanning a very thin patient it is suggested to use what transducer frequency?



Answer
5.0 MHz



The slide features five decorative circles of varying shades of light purple. One circle is empty and positioned above the text 'Liver Pt. 5'. The other four circles are filled and positioned around the text 'The typical AP measurement of the left lobe of the liver is?'.


Liver Pt. 5

The typical AP measurement of the left lobe of the liver is?



Answer

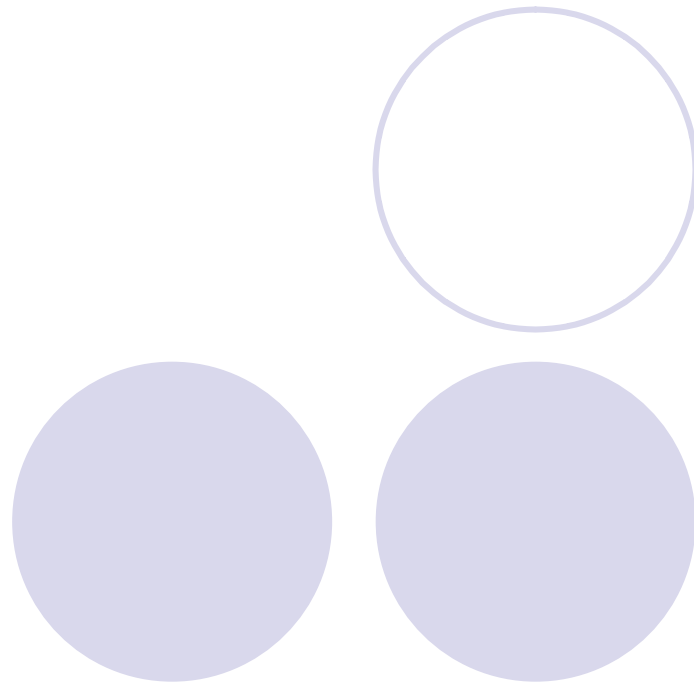
**Does not normally exceeds
6 cm**






GB & Biliary System Pt. 1

What is the normal width of the
gallbladder?



Answer

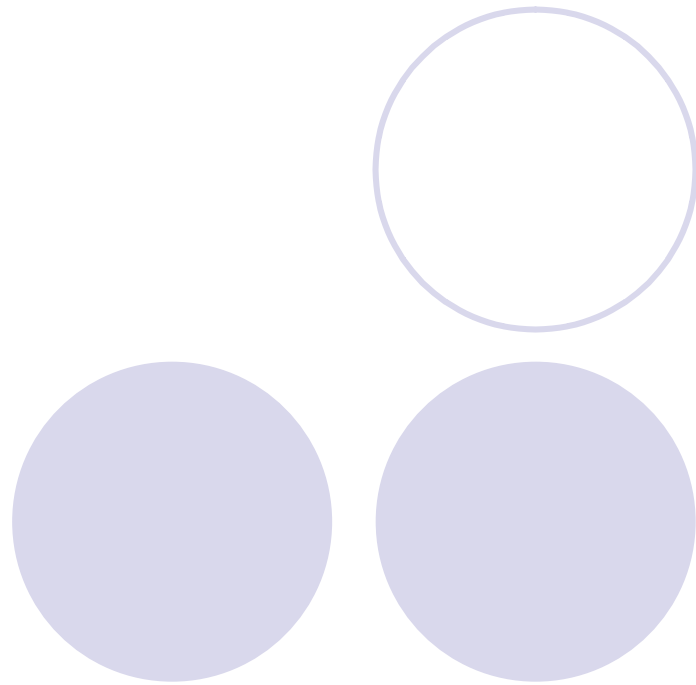
3 – 4 cm






GB & Biliary System Pt. 2

What is the normal length of the gallbladder?



Answer


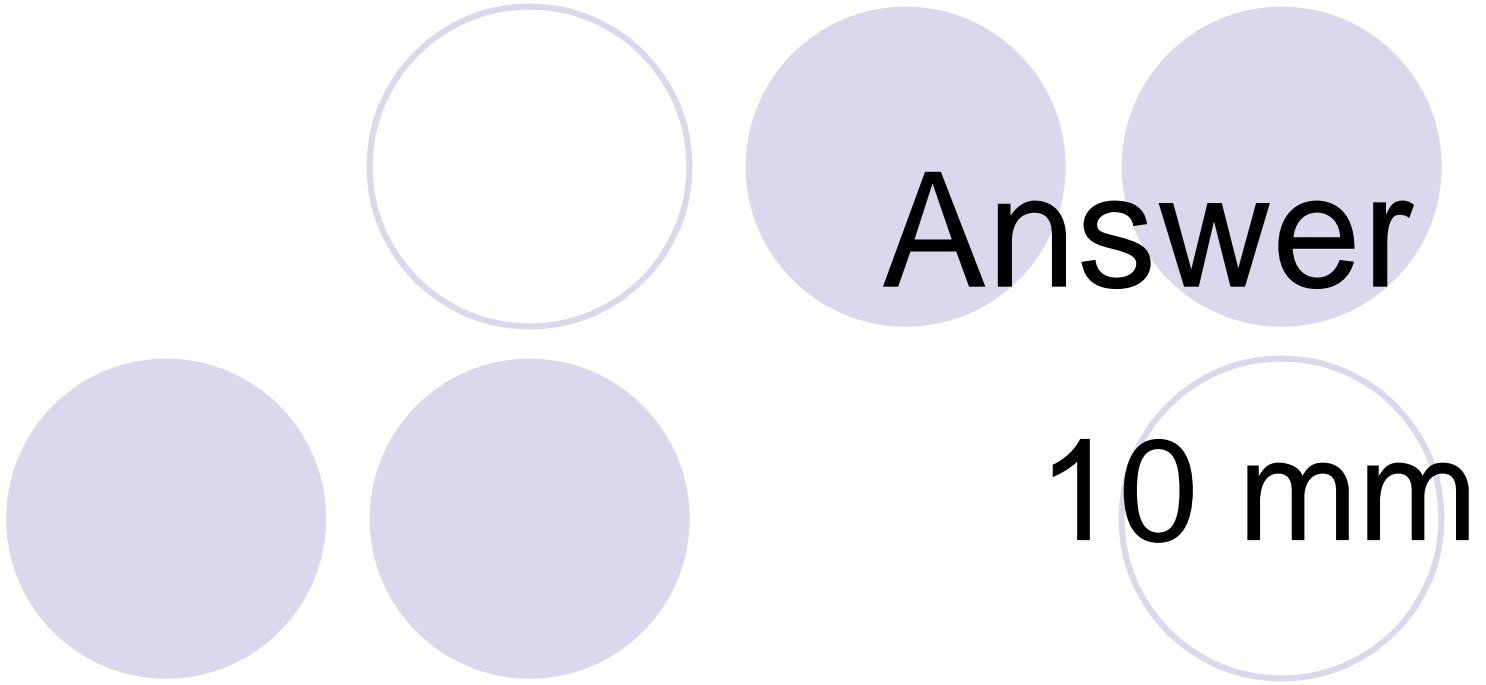
7 – 10 cm





GB & Biliary System Pt. 3

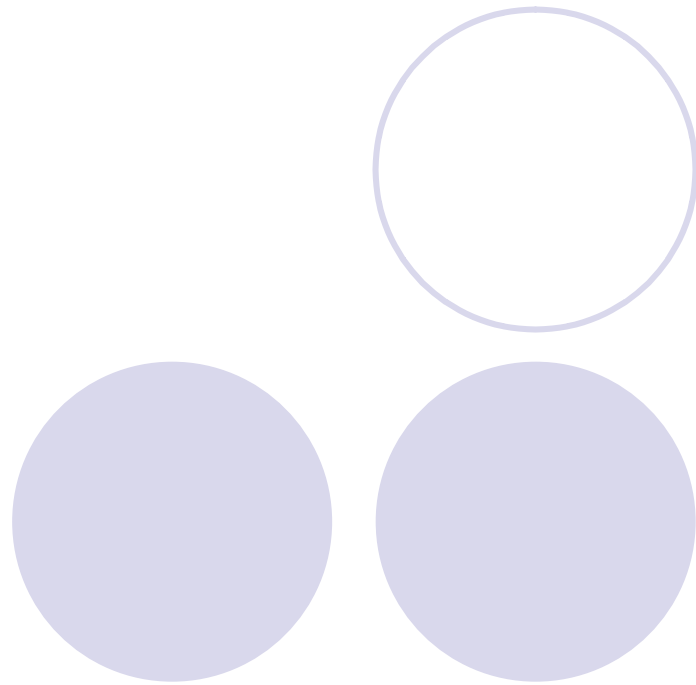
The common bile duct should
not measure more than?






GB & Biliary System Pt. 4

The normal size range for
the hepatic duct is?



Answer

1 – 7 mm






GB & Biliary System Pt. 5

The measurement of the
cystic duct is?



Answer

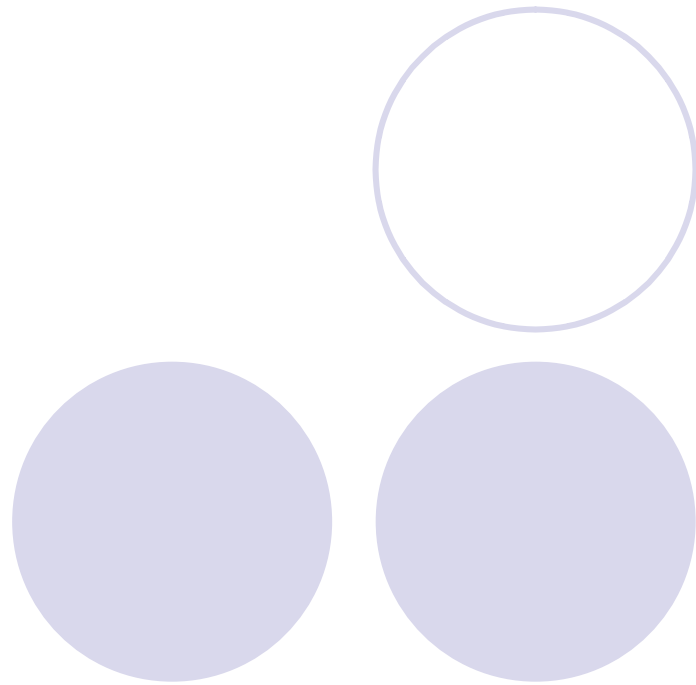
Less than 3 mm






Renal & Thyroid Pt. 1

Typical length for a normal size adult kidney is?





Answer

9 – 12 cm



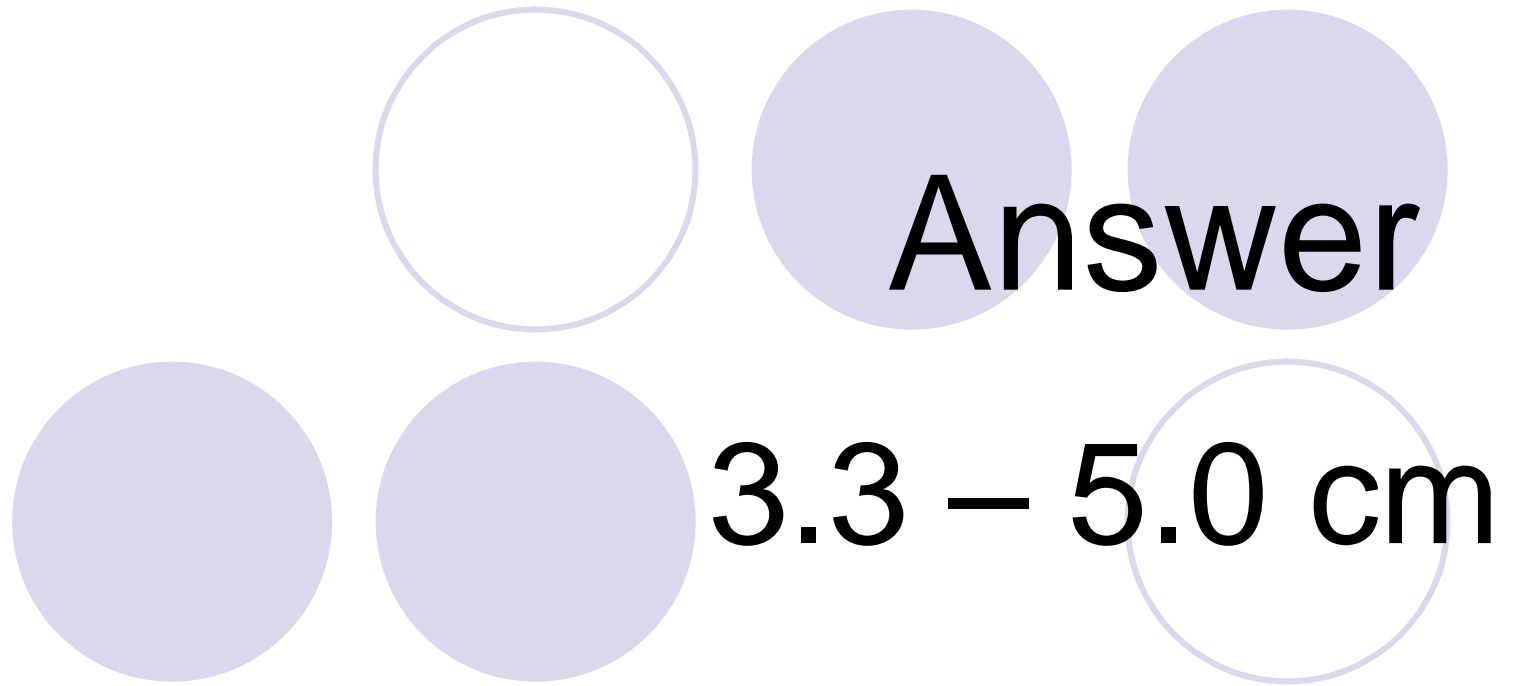
Renal & Thyroid Pt. 2


The adult kidney is usually
how wide?



Renal & Thyroid Pt. 3

What is the length of the normal neonatal kidneys?


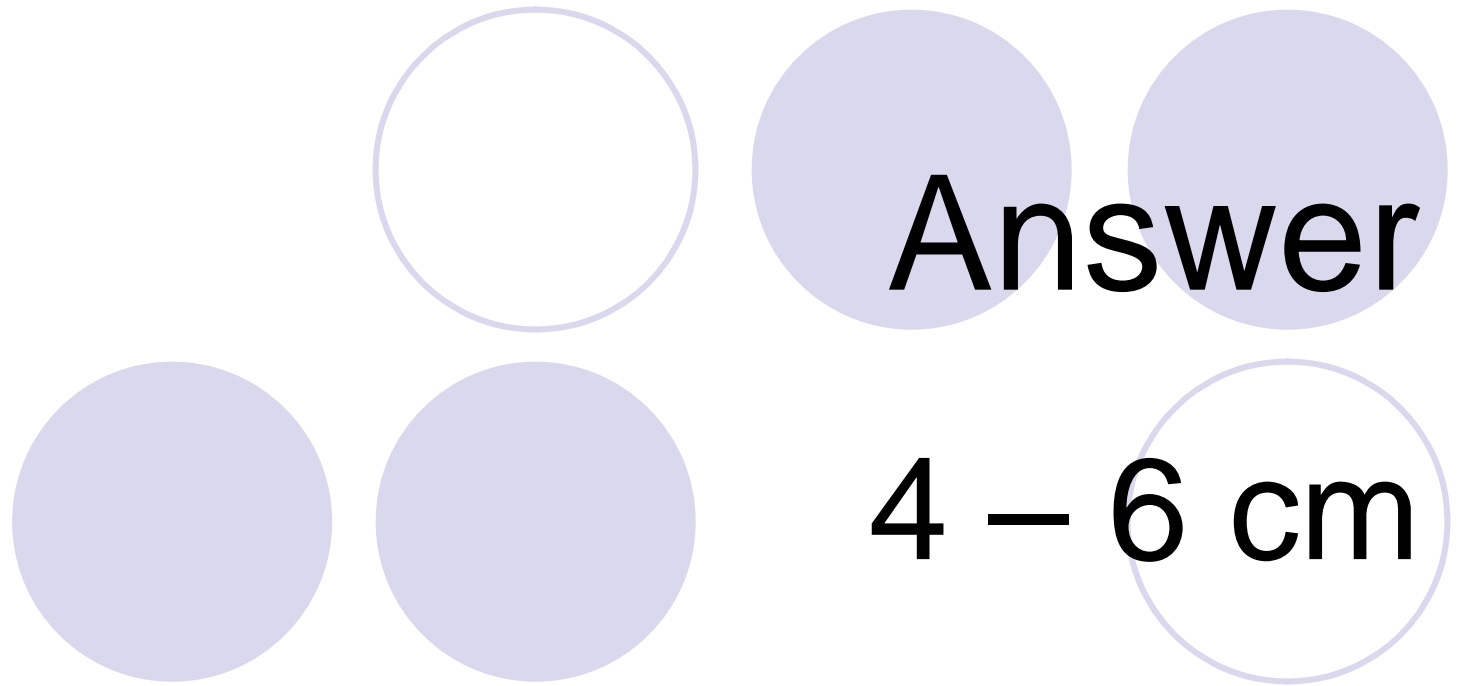
 Answer
3.3 – 5.0 cm





Renal & Thyroid Pt. 4


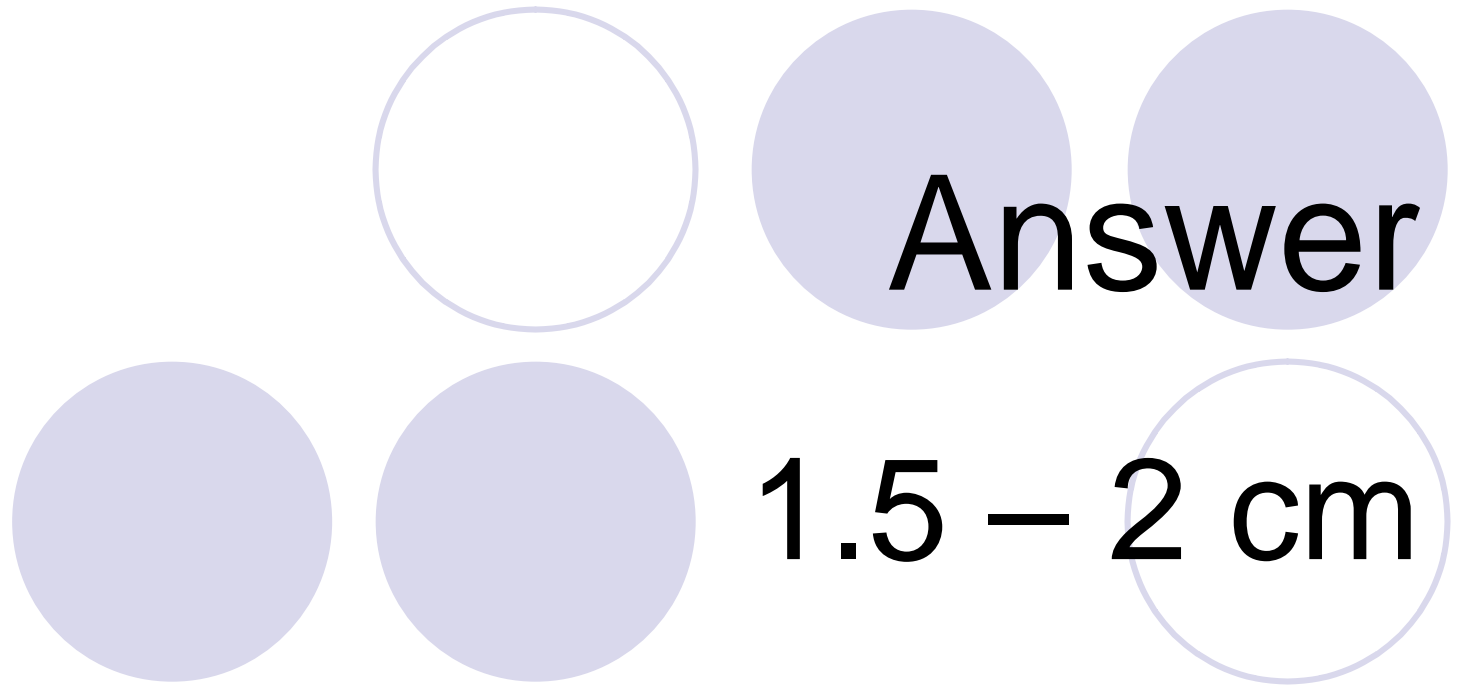
What is the size range for
the thyroid's length?



The slide features six light purple circles arranged in two rows of three. The top row has one hollow circle on the left and two solid circles on the right. The bottom row has two solid circles on the left and one hollow circle on the right. The text is centered over these circles.

Renal & Thyroid Pt. 5

What is the normal width
for the thyroid?


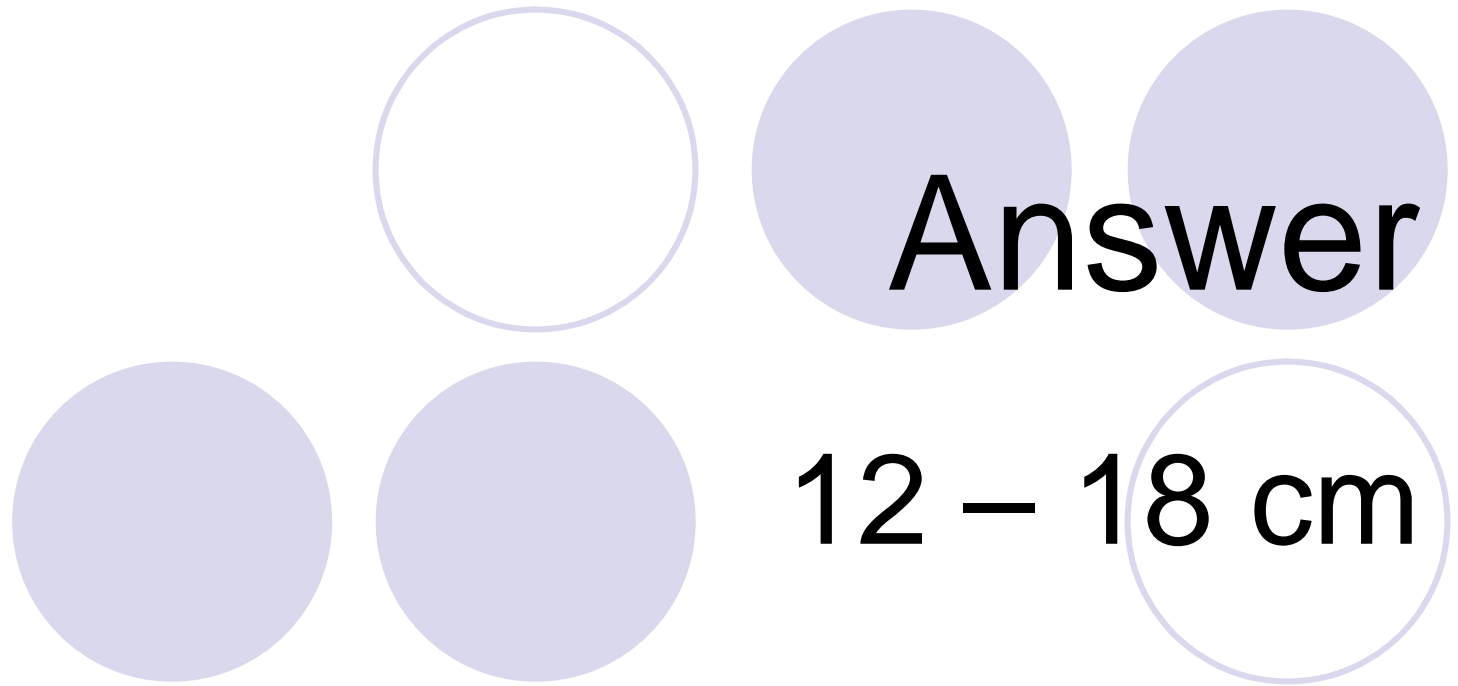




Pancreas & Spleen Pt. 1



The normal size range for the pancreas is?






Pancreas & Spleen Pt. 2




The average length of the spleen is?



Answer

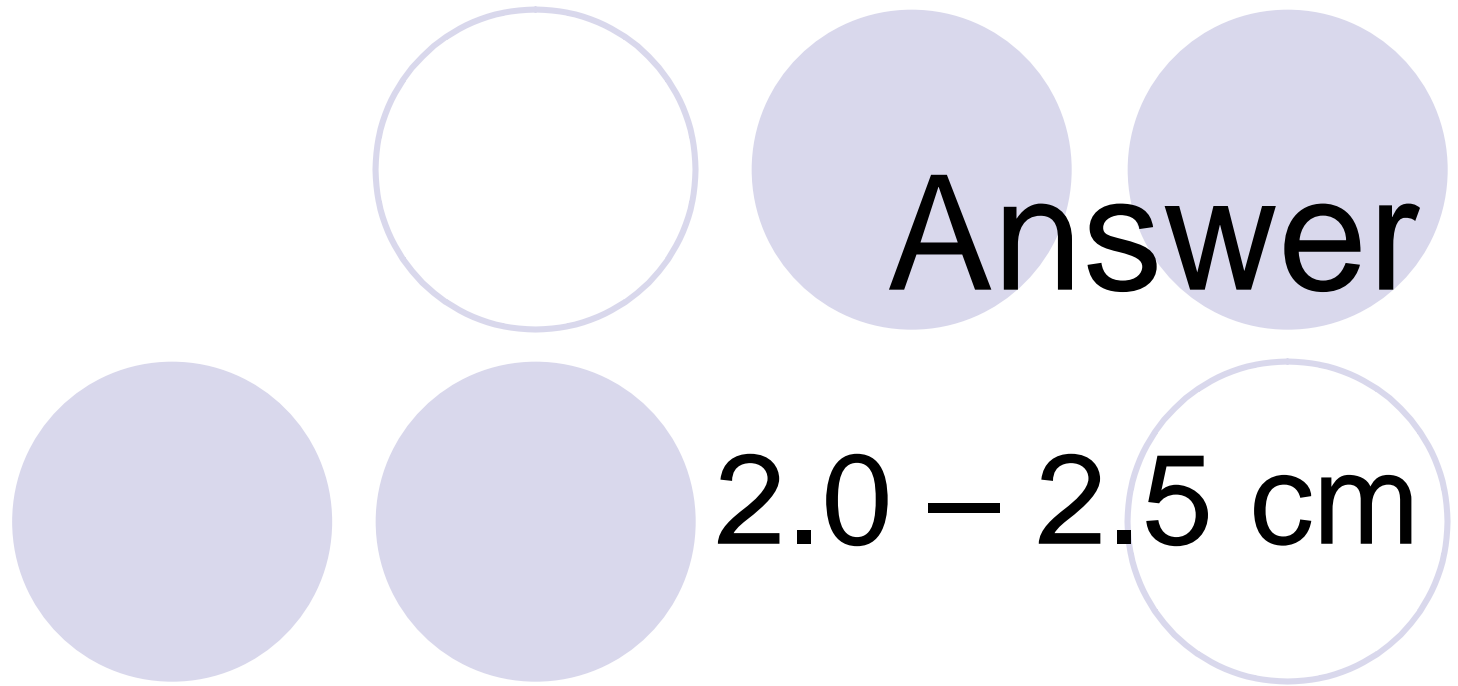
8 – 13 cm






Pancreas & Spleen Pt. 3

The AP measurement of the
body of the pancreas is?

**Answer**
2.0 – 2.5 cm


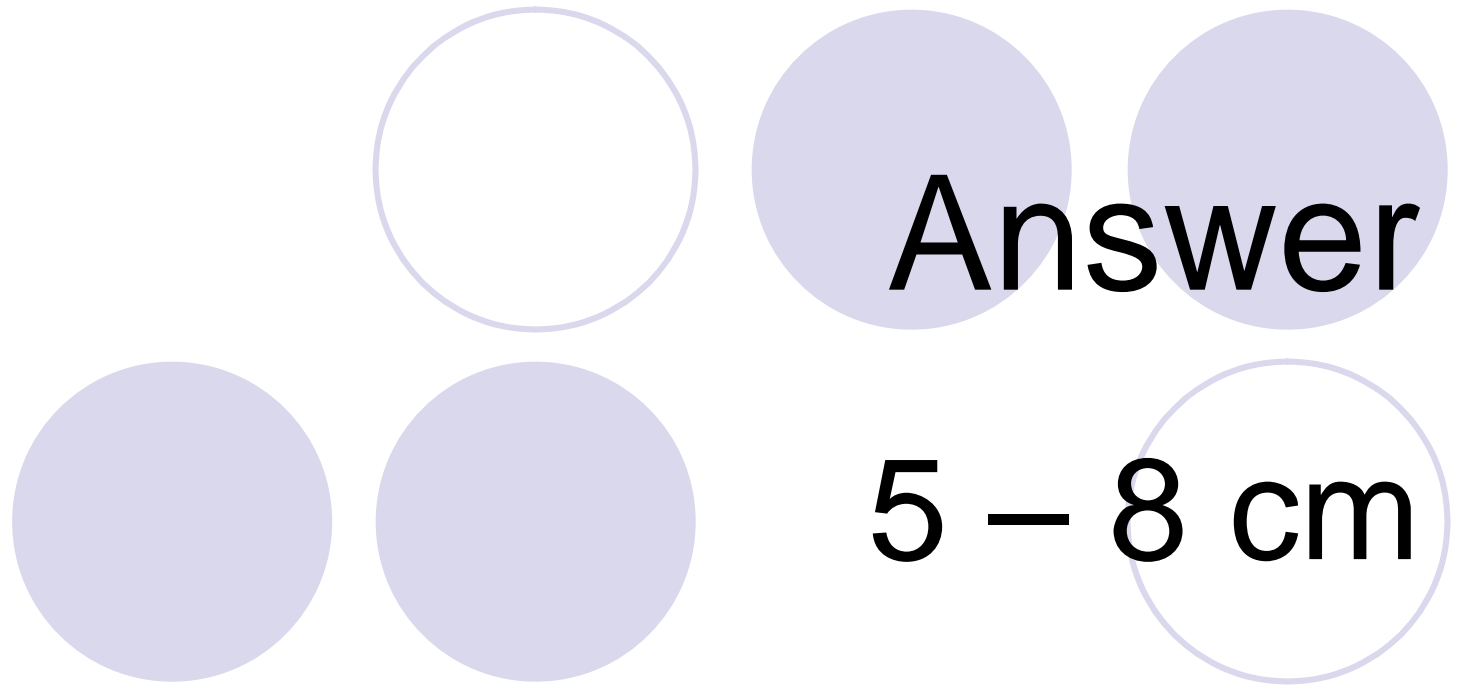




Pancreas & Spleen Pt. 4




The normal width for the spleen is?






Pancreas & Spleen Pt. 5



The measurement of the
pancreatic duct is?

Answer


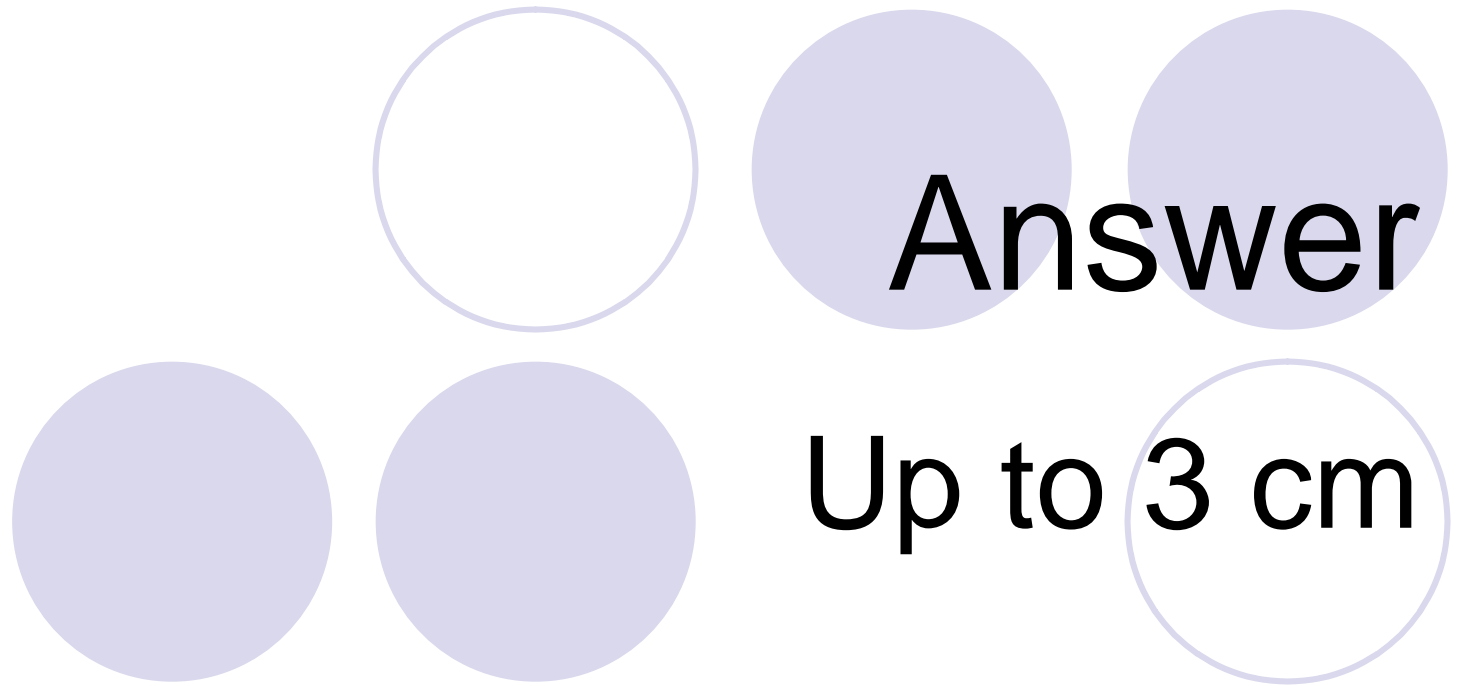
No larger than 3 mm



The slide features five decorative circles of varying shades of light purple. One circle is an outline, while the others are solid. They are arranged in two rows: three in the top row and two in the bottom row.

Anatomy General Pt. 1


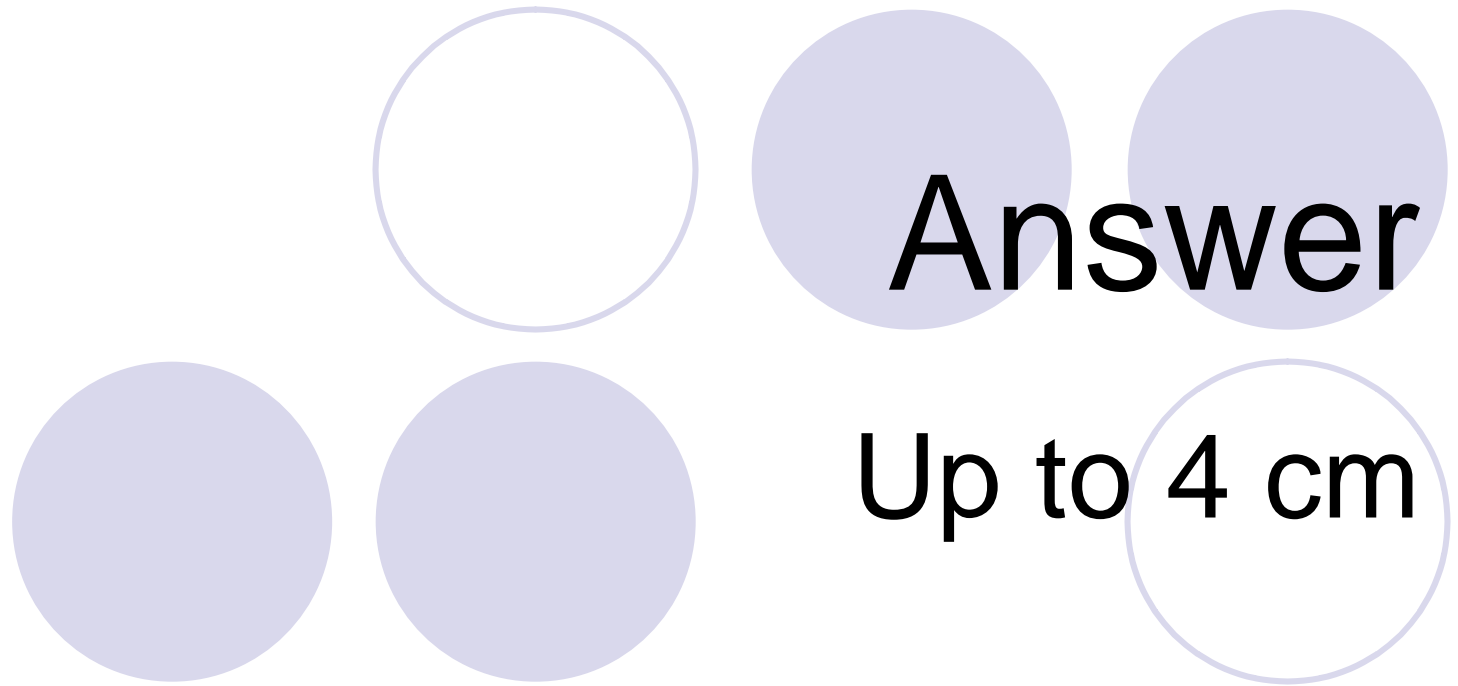
What is the diameter of the
Aorta?






Anatomy General Pt. 2

What is the diameter of the
Inferior Vena Cava?


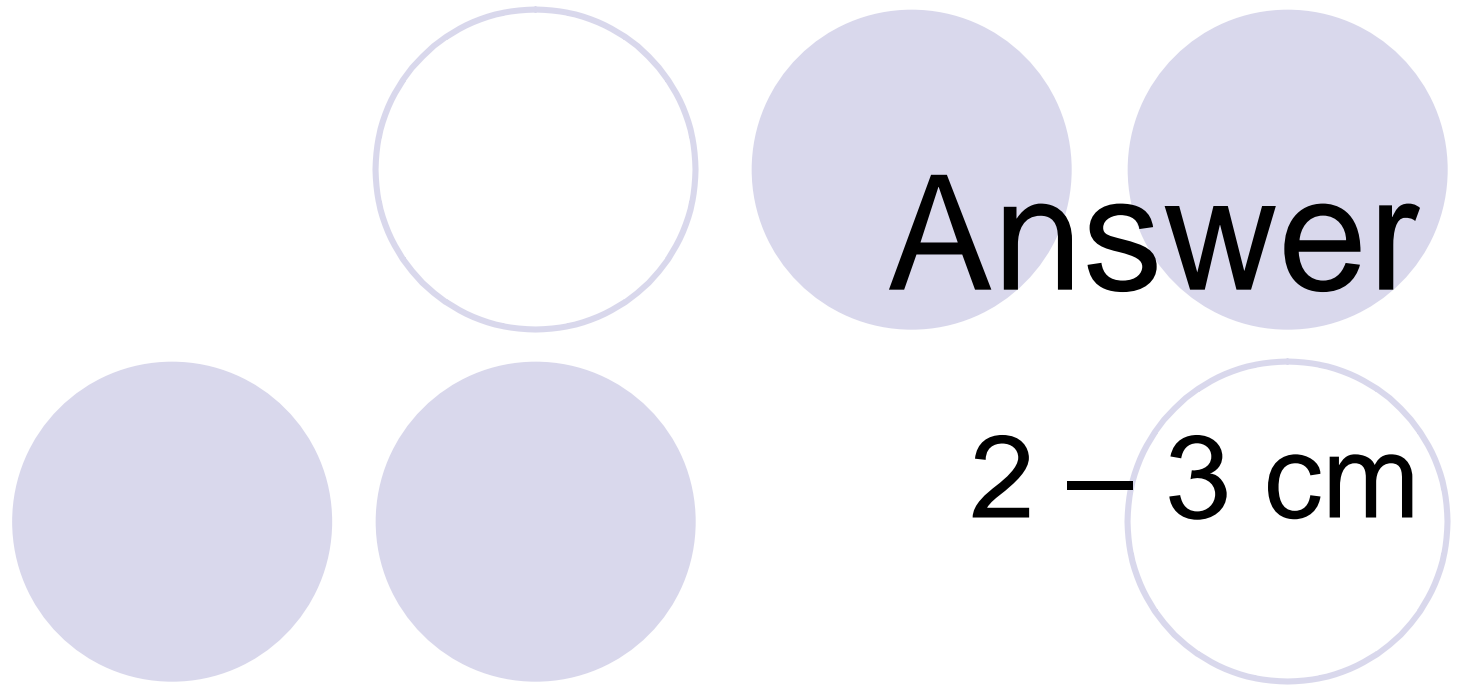




Anatomy General Pt. 3




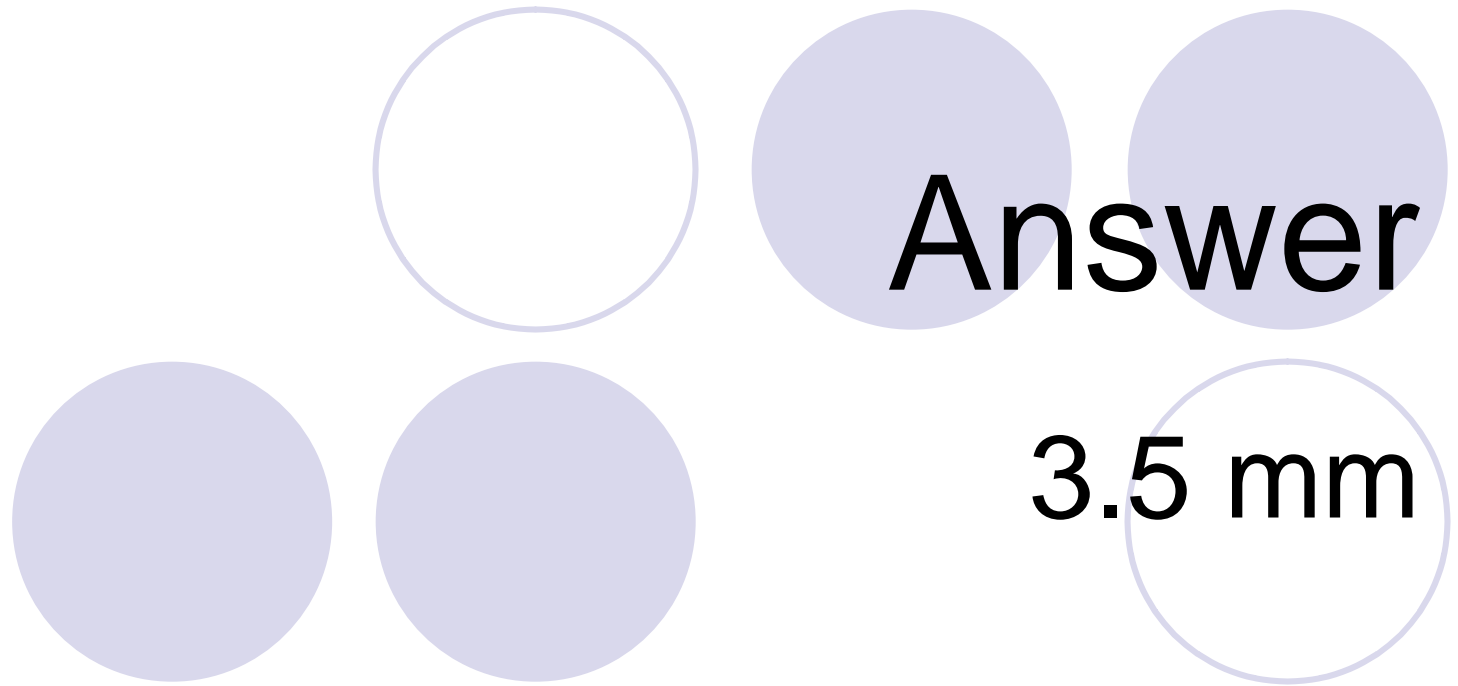
The pylorus is what size in length?





Anatomy General Pt. 4

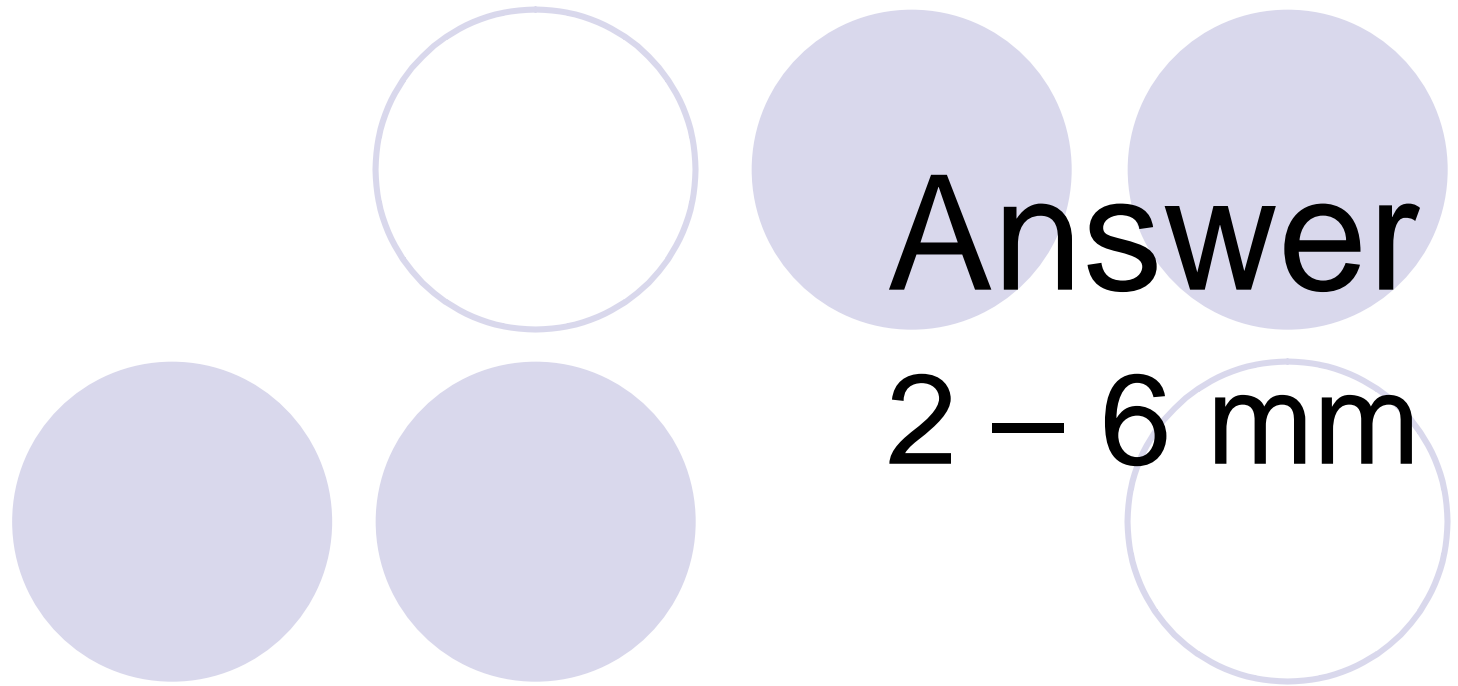
The width of the pylorus
should not be over what size?





Anatomy General Pt. 5

What is the AP measurement for the isthmus of the thyroid?



Answer

2 - 6 mm

